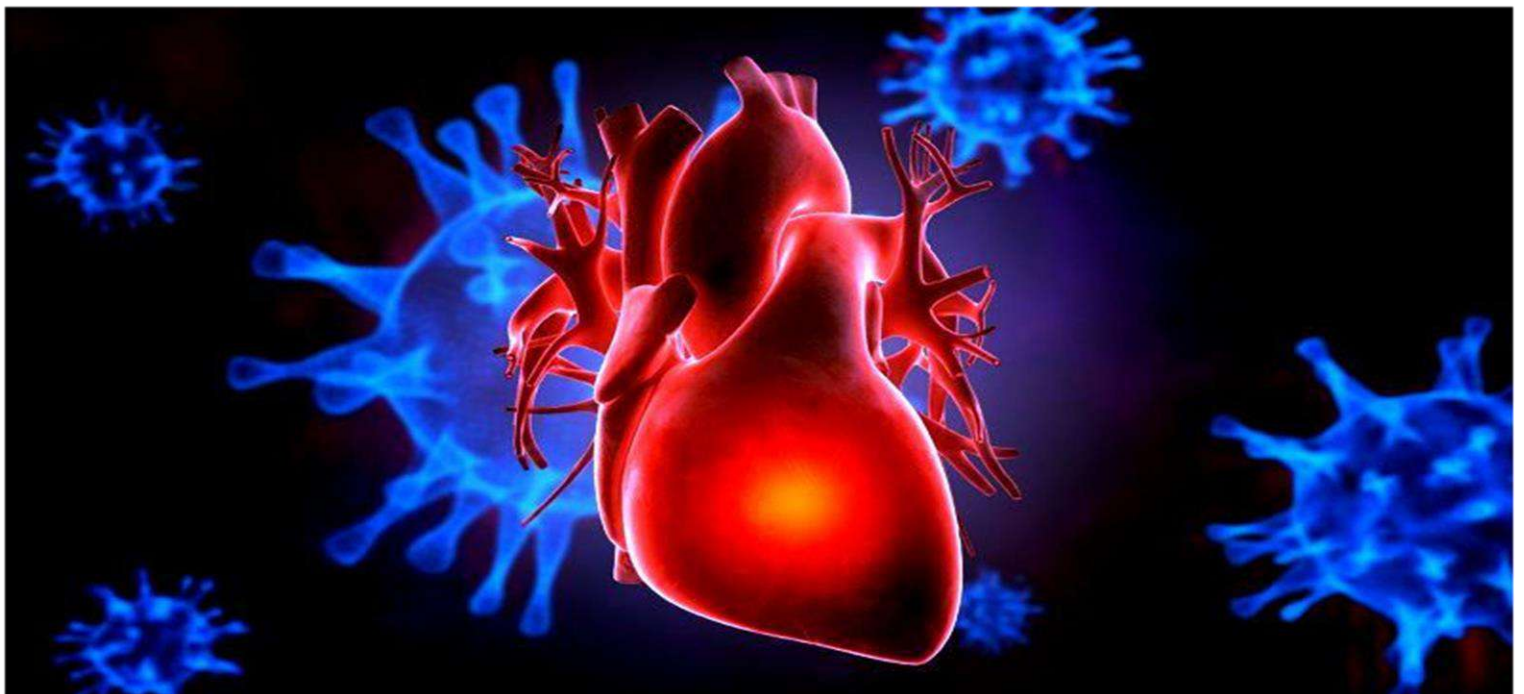




Sri Lankan Journal of Cardiology



Sitaglu

Sitagliptin Phosphate

Tablet

50mg & 100mg



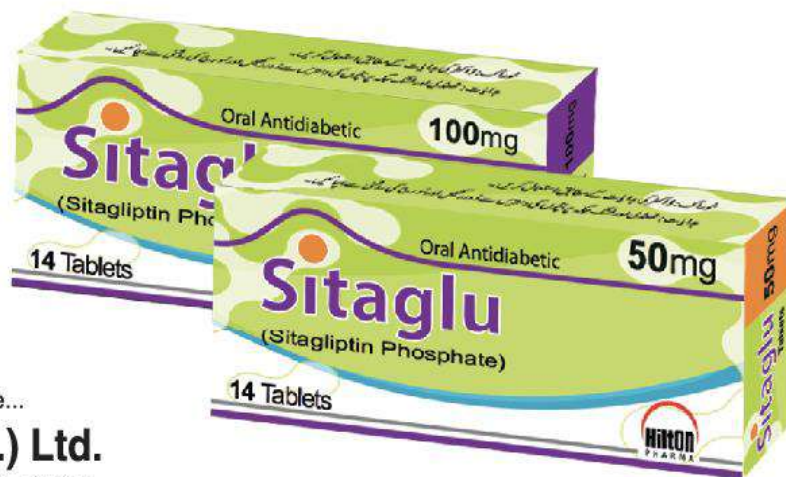4 Goals one T R E E Therapy

Tolerability

Reliability

Efficacy

Endorsements



Working Towards a Healthy Future...

Hilton Pharma (Pvt.) Ltd.

Progressive Plaza, Beaumont Road, Karachi - Pakistan.
UAN: (021) 111-123-000 Web: www.hiltonpharma.com

SLJC Editorial Board

Editor in Chief

Dr Ruvan A. I. Ekanayaka

Consultant Cardiologist

Norris Clinic/ Nawaloka Hospitals PLC.

Editors

Dr Susitha Amarasinghe

Consultant Cardiac Electrophysiologist

Teaching Hospital, Karapitiya.

Dr S A E S Mendis

Consultant Cardiologist

Institute of Cardiology, National Hospital of Sri Lanka.

Dr Naomali Amarasena

Consultant Cardiologist

Sri Jayawardenapura General Hospital.

Dr Mahendra Munasinghe

Consultant Cardiothoracic Surgeon

National Hospital of Sri Lanka.

Dr Dimuthu Weerasuriya

Consultant Paediatric Cardiologist

Lady Ridgeway Hospital for Children.

International editors

Dr Zahid Amin

Consultant Paediatric Cardiologist

Professor and Section Chief

Division of Paediatric Cardiology

Children's Hospital of Georgia

Augusta University, Georgia, USA.

Dr Sundeep Mishra

Department of Cardiology,

All India Institute of Medical Science

New Delhi, India.

Dr Rajesh Rajan

Consultant Cardiologist

President of the Indian Association of Clinical Cardiologists.

Associate editors

Dr Chamara Rathnayake

Consultant Cardiologist

Asiri Central Hospital,

Colombo

Dr Mahen Boralessa

Senior Registrar

Institute of Cardiology, National Hospital of Sri Lanka.

Scope of the journal

by

Dr Ruvan A I Ekanayaka

The scope of this journal will be broadly based in order to realize three objectives.

First and foremost the objective is to publish high quality research which deals with problems which are of universal relevance but with greater focus on work targeting locally relevant problems.

Secondly, the journal will be a forum for cardiologists and other specialists to share their clinical experiences via case reports. Most cardiologists have cases worth reporting for their value in providing insights into pathophysiology, guiding selection of therapeutic pathways and shedding light on problem solving. The journal will encourage such case reports.

The third objective is for this publication to be a fruitful avenue of Continuing Medical Education (CME). The lack of time should not be a limiting factor to assimilate knowledge. The journal will utilize reviews, tutorials, journal scans and updates to provide a well-balanced CME course in Cardiology.

ISSN 2630-7596

Xenglu

Empagliflozin

10mg & 25mg
Tablet



Giant leap

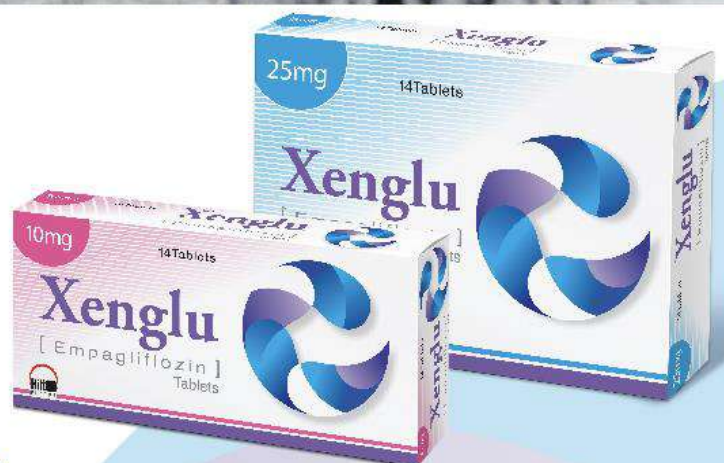in Diabetes
Management



Working Towards a Healthy Future...

Hilton Pharma (Pvt.) Ltd.

Progressive Plaza, Beaumont Road, Karachi - Pakistan.
UAN: (021) 111-123-000 Web: www.hiltonpharma.com





Page

Reviews

- 004- | **Management of patients with patent foramen ovale**
E. Chamara Ratnayake

- 007 | **Atrial Fibrillation Management**
Rohan Gunawardena

Research

- 013 | **Malnutrition in Children with Congenital Heart Disease - is it a concern?**
H.M.S.L Jayasekara, T.G Samarasekara, S.N Perera, Renuka Jayatissa, K.H De Silva

- 018 | **Effect of Anticoagulation on the Lifestyle in Sri Lankan patients with Mechanical Valves - Prevalence of Nonfatal Complications of Anti-coagulation and the Episodes of deranged INR among the followed up patients with Mechanical Prosthetic Heart Valves**
Palinda Bandarage, Mahendra Munasinghe

Updates

- 022 | **COVID -19 Practice Points and Updates for Cardiologists**
G Reshmaal Gomes Cumararatunge

- 036 | **COVID-19 and Acute Coronary Syndromes: Implications and considerations**
F. Aaysha Cader

CONTENTS

June 2020

Volume 3 Issue 2

Page

Updates

- 044 | **Rapid Journal Scan**
From the Editorial desk

Tutorial

- 052 | **COVID-19 Basics for Cardiologists**
From the Editorial desk

Case Reports

- 057 | **A case series of Left Atrial Appendage (LAA) Device closure in Sri Lanka**
W.G Ranasinghe, R.Shetty, V.E Paul, C.J Ponnampuruma, R.S Paranamana, S. Karunaratne, T.D.P Vithanage, D.D.E Colombage, S. Sajeev, W.F.R.D Sovis, V.P Jayasinghe, H.T.R.P Liyanage

- 060 | **Acute Anterior ST Elevation Myocardial Infarction complicated with Ventricular tachy-cardia due to Diffuse Coronary Artery Spasms**
C.P Wickramarachchi, S Senanayake, K. Lokuketagoda, J. Herath, N. Amarasena S. Kottegoda



Case Reports

- 062 | **Distortion and Fracture of the proximal portion of a stent in the left main coronary artery that was successfully managed with a conservative approach**
M.D.S Boralessa, S. Withanawasam
- 066 | **Left Anterior Descending Artery (LAD) lesion presenting as acute Inferior ST Elevation Myocardial infarction (STEMI).**
A.P.N De Vas Goonewardane, G.I.D De Silva, J.H Herath, S.R Kottegoda
- 068 | **Retrieval of a Stalled Rotablator Burr through a modified Double Guide Technique.**
T.Kabir, V.Panoulas, A.P.N De Vas Goonewardane
- 070 | **A case of Peripheral Vascular Intervention for Chronic Total Occlusion of the Popliteal Artery**
D.M. Liyanage, N. Fernando, T. Vaikunthan, L.S. Kularatne, T. Pereira
- 073 | **A 27-year-old Lady with Non-atherosclerotic Spontaneous Left Anterior Descending Coronary Artery Dissection.**
I.H.D.S Prabath, N. Fernando, T. Pereira

CONTENTS

Continued.....

June 2020

Volume 3 Issue 2

Page

- 075 | **Idiopathic Calcific Constrictive Pericarditis, successfully treated with Surgical Pericardiectomy**
N.U.A. Dissanayake, G.Galappaththy, A.K Pathirana, R.Y. De Silva, C.I.H. Siriwardane, I.U.K. Marasinghe
- 079 | **Inferior STEMI due to acute occlusion of an anomalous left circumflex artery arising from the right coronary cusp and percutaneous coronary intervention of the anomalous culprit coronary artery**
M.D.S Boralessa, S.Withanawasam
- 082 | **Rotational Atherotomy (Rotablator) assisted successful PCI in a Heavily Calcified and Stenosed Right Coronary Artery**
C.P.Wickramarachchi, S.Gambhir, K.Lokuketagoda, J.Herath, N.Amarasena



Brief Reports

084

Clinical and Echocardiographic patterns of presentation and Immediate outcomes of Coarctation of aorta patients following Transcatheter intervention in a Tertiary Cardiac Intervention centre in Sri Lanka
S.A.E.S Mendis

Author Guidelines

086

Submitting to the Journal

CONTENTS

Continued.....

June 2020

Volume 3 Issue 2



Review

Management of patients with patent foramen ovale

E Chamara Ratnayake

Asiri Central Hospital Norris Canal Road, Colombo 10, Sri Lanka

Corresponding author: Dr. E Chamara Ratnayake Consultant Cardiologist

E mail: chamara.ratnayake@gmail.com

Introduction

Patent foramen ovale (PFO) has been known to be involved in the pathogenesis of multiple medical conditions. However, they have remained an enigma with no clear guidance as to how best to approach them. The most conclusive evidence is in its pathogenesis towards left sided thromboembolism, mainly leading to cryptogenic cerebrovascular accidents. As of 2019, there were no official position papers on its management mainly because the majority of evidence were observational and had disparate or contradictory guidance. To address this concern, the European Association of Percutaneous Cardiovascular Interventions (EAPCI) with the collaboration of eight scientific societies and experts introduced a position statement on the management of PFO published online (ahead of print) in October 2018 on the European Heart Journal. This review article will summarize its content.

PFO related cryptogenic left circulation thromboembolism : Definition, pathogenesis and evidence

The Cryptogenic ischaemic left circulation embolisms are defined as any definite ischaemia (symptomatic or asymptomatic) occurring in an arterial bed which lacks a known cause despite investigation. It is recommended that any patient who presents with the above be screened for PFO and if found to be causative be reclassified as PFO related and not cryptogenic.

The possible pathogenesis of thromboembolism related to PFO is multifactorial. They are (but not limited to): paradoxical embolism, thrombus forming within the PFO, left atrial dysfunction, and atrial arrhythmias.

Multiple clinical observational and randomized clinical trials have supported the theory that PFO are indeed culprits in leading to stroke and closure leads to decline in stroke recurrence compared to medical therapy.

General approach to PFO management: Common sense should prevail

PFO is a common condition and may be seen in up to 25% of the general population. Hence, it may coexist as an innocent bystander in a patient with unexplained left sided thromboembolism. It should be considered innocent until proven guilty. It is recommended to involve a multidisciplinary team including interventional cardiologists, stroke physicians, general physicians and any other speciality demanded by the patient's clinical manifestation.

In all clinical scenarios, the two main axes guiding assessment and treatment of PFO should be: 1) the probability that any PFO has a relevant role in the observed clinical picture; 2) the likelihood that the observed clinical event will recur.

For patients with the highest probability of both, closure of the PFO should be advised. For patients with the lowest probability, medical therapy should be considered. For patients with intermediate probabilities, clinical judgement is required to allow good decision with the best interest of the patient at heart.

Diagnosing PFO: The tools

Diagnosis of PFO is mainly required for the guidance of treatment. Multiple techniques have been advocated but the highest quality evidence stems from the use of two: Contrast enhanced transoesophageal echocardiography (c-TOE) and Contrast enhanced transcranial doppler (c-TCD).

Of the two, c-TOE remains the best way of visualising the inter-atrial septum and any shunt. However, a metanalysis has shown that the accuracy of c-TOE compared to autopsy and cardiac surgery and catheterisation had a sensitivity of 89%. The slight inaccuracy has been attributed to the inability of some patients to perform an adequate Valsalva manoeuvre.



The following features should be assessed during c-TOE to assist in decision making:

- PFO morphology: size, location, length of the tunnel
- Spatial relationship and distances between the PFO and the aortic root, vena cava, valves and the free walls of the atrium
- Comprehensive evaluation of the atrial septum, including inspection for atrial septal aneurysms, movement, and other atrial septal defects
- Presence/absence of a Eustachian valve and/or Chiari network
- Thickness of the septum primum and secundum
- Colour Doppler evaluation of the shunt at rest and after a Valsalva manoeuvre

The use of c-TCD is mainly limited to assessing the shunt. A metaanalysis of 29 studies however yielded a sensitivity of 94% and specificity of 92% compared to c-TOE. The use of contrast-transsthoracic echocardiography (c-TTE) provides a low diagnostic yield with a sensitivity of 88% and specificity of 82%.

Unfortunately due to the low quality of evidence, there still remains a question as to what would be proposed as the gold standard in diagnosis and management. Current evidence suggests a precise diagnosis might need a combination of techniques. The following algorithm has been proposed:

- c-TCD negative – No need of further evaluation
- If c-TTE positive → c-TOE
- If c-TCD positive → c-TOE
- If c-TTE negative or equivocal → c-TCD (And as above)

Apart from imaging studies, identifying atrial fibrillation (AF) is important because recurrences of left circulation embolism are, in the majority of cases, due to left atrial appendage thrombosis instead of paradoxical embolism. A routine 12-lead electrocardiogram (ECG) and either inpatient cardiac telemetry or 24-hour Holter monitoring are sufficient to diagnose permanent AF and sufficiently long transient AF episodes.

Risk factors associated with PFO-mediated stroke: How likely is it?

Patient characteristics

- Age <55 years
- Absence of other risk factors or comorbidities for stroke

Imaging stroke pattern

- Cortical infarcts
- (Neither the localization nor type of infarct pattern in grey or white matter was specific for PFO embolism in observational studies)

Characteristics of the PFO

- Atrial septal aneurysm
- Moderate-severe shunt
- Large PFO
- Atrial septal hypermobility
- Presence of Eustachian valve and/or Chiari malformation
- Long PFO tunnel

Best management strategy: Medical or interventional?

Prior to embarking on management strategies, it is best to possess a unified diagnostic work up for patient who present with left circulation thromboembolism (Figure 1).

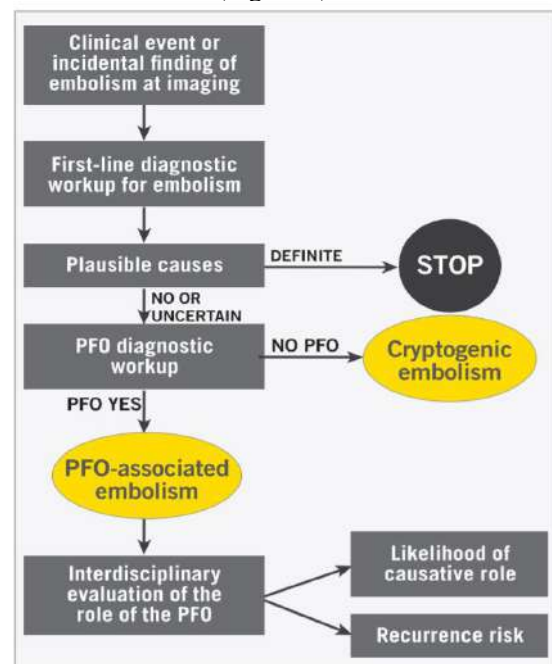


Figure 1: Algorithm for the diagnostic work-up for left circulation thromboembolism



Upon confirmation, a decision on medical vs interventional therapy can be made.

Medical therapy

Medical management is recommended in patients deemed low or uncertain risk for causal link or recurrence.

The choice has been between antiplatelet agents versus oral anticoagulants (OAC). Most metanalysis shows superiority of OACs although the quality of evidence is considered to be low. The main complication associated with medical therapy is bleeding. However, a recent metanalysis has shown a very low prevalence of 1.1%, mainly attributed to the young age of patients and short follow up. Thus, this should be interpreted with caution. The stroke recurrence rate with medical therapy in most trials ranged between 3-5% annually.

Percutaneous closure

PFO closure is recommended in patients deemed to be at high risk for causal link or recurrence and between the ages of 18-65 years. Percutaneous closure is currently the method of choice. There is no evidence to support surgical closure as first line treatment unless it is done on an incidentally found PFO during another valvular surgery.

Primary success rates for percutaneous closures approach 100% and complete closure is seen in approximately 95% of patients at one year. The recommended devices thus far are AMPLATZER and PFO Occluder, as they have relative less rates of residual shunt compared to other devices.

The stroke recurrence rate following percutaneous closure is very low, with most trials finding a rate of less than 2% annually.

The most common complication associated with percutaneous closure is atrial fibrillation, most often occurring with the first 45 days. Procedure related complications occur rarely, with device thrombosis and device embolism being the most common. The risk of long term mortality is less than 1 in 1000.

Dual antiplatelet therapy is recommended for 3-6 months post procedure and a single antiplatelet is recommended for up to 5 years.

Empirically, antibiotic prophylaxis against endocarditis before an invasive procedure or

intervention should also be considered routinely in all cases within the first six months after the implantation and, probably, beyond six months in patients with a residual shunt.

Conclusion

The best practice for the management of patients with apparent cryptogenic left circulation thromboembolism attributed to PFOs remain controversial. The current guideline and position statement seeks to shed some clarity in a field that lacks quality data and large scale clinical trials. The most important aspect as with any other cardiovascular disease is risk assessment followed by appropriate investigations and treatment. The position statement also acknowledges the scarcity of data and strongly recommends research priorities with larger scale RCTs which would indeed help in better understanding and thus treatment of a miniscule hole in the heart with the potential to cause catastrophic consequences.

References

1. PRISTIPINO, C., SIEVERT, H., D'ASCENZO, F., LOUIS MAS, J., MEIER, B., SCACCIATELLA, P., HILDICK-SMITH, D., GAITA, F., TONI, D., KYRLE, P., THOMSON, J., DERUMEAUX, G., ONORATO, E., SIBBING, D., GERMONPRE, P., BERTI, S., CHESSA, M., BEDOGNI, F., DUDEK, D., HORNUNG, M., ZAMORANO, J., EVIDENCE SYNTHESIS, T., EAPCI SCIENTIFIC, D., INITIATIVES, C. & INTERNATIONAL, E. 2019. European position paper on the management of patients with patent foramen ovale. General approach and left circulation thromboembolism. *Eur Heart J*, 40, 3182-3195.



Review

Atrial Fibrillation Management

Rohan Gunawardena

Cardiology unit, National Hospital, Sri Lanka

Corresponding author: Dr. Rohan Gunawardena, Consultant Cardiac

Electrophysiologist

E mail: rohan.gunawardena@yahoo.com

Introduction

Atrial fibrillation (AF) remains the most common cardiac rhythm disorder in the world. It's prevalence in the western population is 1 - 2% rising with increasing age to 9% after 80 years ⁽¹⁾. The prevalence in Sri Lanka has not been studied but would be expected to be similar to western rates and perhaps higher considering that we still have a considerable population with rheumatic mitral valve disease. The impact of AF is underestimated, and new evidence suggests that death rates are doubled in patients with AF and while the stroke risk is increased, strokes associated with AF are more severe. It is believed that up to 1 in 5 of all strokes are due to AF, even if AF is not documented at the time. Palpitations, reduced exercise capacity and vascular dementia associated with AF, significantly impair quality of life. Left ventricular function is generally impaired due to irregular, fast ventricular rates compounded by reduced LV filling due to loss of atrial systole. The economic impact on health services and families caring for patients' is generally underestimated ⁽²⁾.

Classification of AF ⁽³⁾

The new classification is designed to distinguish AF according to the clinical status of the patient. This is useful for the practicing physician as it allows decisions to be made about the investigations and management strategies for individual patients.

First diagnosed AF – this is a patient presenting for the first time to the physician with AF, irrespective of whether there had been previous undiagnosed symptoms and symptom severity. It is at this point that certain investigations need to be done, patient is categorized into either paroxysmal, persistent or long-standing persistent AF and a strategy be made for long term management.

Paroxysmal AF – AF is self-terminating, usually within 48 hours but can last for up to 7 days. Beyond 48 hrs, the chance of self-termination is

low and anticoagulation and cardioversion need to be considered. Note that if the patient is in AF at first presentation, it may not be immediately clear as to whether it is paroxysmal or persistent.

Persistent AF – AF lasting longer than 7 days or needs medical or electrical cardioversion.

Long standing persistent AF – AF has lasted for more than one year and a decision has to be made whether to attempt rhythm control.

Permanent AF – In this case a decision has been made by the physician and patient to accept AF and not to attempt rhythm control. If at any time in the course of treatment a decision is made to attempt cardioversion then the category changes to long standing persistent.

Initial assessment

A detailed history, examination and blood pressure measurement needs to be taken to categorize the type of AF, severity of symptoms and to elicit possible risk factors and complications (table 1) and assess risk of stroke. The EHRA (European Heart Rhythm Association) score (table 2) is useful for assessing symptoms. The symptoms considered in this score are those that would be alleviated by either rhythm or rate control. The assessment of stroke risk is also important at this time.

Is there a precipitating factor such as exercise, emotion or alcohol

Are symptoms during episodes moderate or severe (see table 2)

How frequent are symptoms and how long do they last

Is there a history of coronary artery disease, rheumatic valvular disease, hypertension, diabetes, peripheral or cerebral vascular disease, stroke or TIA or asthma or COAD

Is there a family history of AF

Table 1 – Assessment of precipitating factors and complications



EHRS Class	Symptoms
I	No symptoms
II	Mild symptoms – normal daily activity not affected
III	Severe symptoms – daily activities affected
IV	Disabling symptoms – normal daily activities discontinued

Table 2 - EHRA score of AF related symptoms

Anti-thrombotic therapy

It is worthwhile spending some time to discuss the assessment of stroke risk as this is a contentious and somewhat confusing issue. In all patients with mitral valvular heart disease anticoagulation with an oral anti-coagulant (OAC) is recommended in the presence of mitral stenosis or clinically significant mitral regurgitation. In patients with non-valvular AF various studies have been done to assess risk factors and the effectiveness and risks of OAC with a vitamin K antagonist (VKA) versus aspirin and clopidogrel. Perhaps the most useful for practicing physicians is the CHA₂DS₂VASc score⁽⁴⁾ (table 3). If the score is ≥ 2 , then OAC is recommended. If the score is 1, aspirin 100mg will suffice though OAC is preferred. Those with a score of 0 do not need OAC or aspirin.

Risk factor	Score
Congestive heart failure/LV dysfunction	1
Hypertension	1
Age ≥ 75	2
Age ≥ 65	1
Diabetes mellitus	1
Stroke/TIA/Thromboembolism	2
Vascular disease	1
Sex - female	1

Table 3 – CHA₂DS₂VASc Score

It is now established that OAC is superior to antiplatelet therapy, either aspirin alone or aspirin plus clopidogrel with no difference in bleeding events. The novel oral anticoagulants (NOVACs), the direct thrombin inhibitors, Dabigatran, Rivaroxaban and Apixaban have been approved by the FDA. They all have similar efficacy as Warfarin and a better bleeding profile. The advantage of this group of drugs is that there is no need for monitoring such as PT/INR though reversal is more difficult than warfarin.

They can be used as first line therapy or in patients who have fluctuating INR's or intolerant of warfarin. The only indication for combined therapy with aspirin/clopidogrel is in patients with a CHA₂DS₂VASc score ≥ 2 but who may be considered as a high risk for bleeding. It is also important to realize that the stroke risk is same for paroxysmal, persistent and permanent AF. The ideal international normalized ratio (INR) is considered to be 2 – 3. INRs below 2 have been shown to increase the stroke risk by twofold and intracranial bleeding increases with INRs > 3.5 . Another area of concern is the use of OACs in the elderly. This is driven by fear of intracranial haemorrhage due to falls and other co-morbidities. A useful tool is the 'HAS BLED' scoring system (table 4) to assess risk of bleeding. A score of ≥ 3 indicates a high risk⁽⁵⁾.

Letter	Clinical characteristic	Score
H	hypertension	1
A	Abnormal renal or liver function (1 point each)	1 or 2
S	Stroke	1
B	Bleeding	1
L	Labile INRs	1
E	Elderly (age >65)	1
D	Drugs or Alcohol (1 point each)	1 or 2

Table 4 - HAS-BLED Score for assessing risk of Bleeding

Initial investigations

The 12 lead ECG will show the ventricular rate during AF and indicate the state of AV conduction. A very slow ventricular rate in the absence of rate limiting drugs suggests AV node dysfunction. Evidence of ischemia and ventricular pre-excitation should be noted. An echocardiogram is useful to identify mitral valve disease, atrial dilatation, LV hypertrophy, LV dysfunction and evidence of cardiomyopathy. An FBC, TSH and FBS would also be reasonable tests at this time.

Acute management

The decision to treat acute AF will depend on patient's symptoms and ventricular rate. It is preferable for the ventricular rate to be between 80 – 100 bpm. However, if the patient is in EHRA 1 or 2 and has no cardiac dysfunction, a ventricular rate above 100 is temporarily acceptable.



In situations where AF is secondary (Surgery, Respiratory tract infection) and expected to resolve spontaneously, rate control with an oral beta-blocker or non-hydro pyridine calcium channel blocker is adequate. In patients who are very symptomatic IV verapamil can be used. IV metoprolol is also very useful but not freely available in Sri Lanka.

In patients with depressed LV function or haemodynamic instability, achieving sinus rhythm is desirable. This may also be the case in patients presenting <48 hours after onset of AF. IV flecainide or propafenone have the most success (62-94% and 41-91% respectively) in pharmacologically converting AF to Sinus Rhythm. Neither is available in Sri Lanka at present which leaves Amiodarone as the only alternative. Amiodarone is the preferred choice for patients with IHD or impaired LV function. Though efficacy rates of up to 90% have been reported conversion is delayed compared to flecainide or propafenone. Amiodarone should always be given through a central venous line and though recommended to be given over one hour, practically it is more effective giving the bolus (3-5mg/Kg) over a few minutes followed up by an infusion of 50mg/hr. To maintain SR, simultaneous oral amiodarone should be started at 100-200mg tds. As amiodarone can cause hypotension, heart block and intraventricular conduction defects this regime should only be undertaken where monitoring facilities are available.

In patients with AF and a slow ventricular rate the possibility of a concomitant AV node dysfunction must be suspected. Atropine may work transiently, but in most cases temporary pacemaker insertion and DC cardioversion is needed. In some patients AF is part of Sick Sinus Syndrome and successful cardioversion may be followed by sinus bradycardia or sinus arrest.

In patients who are very unstable and need rapid control of a very fast heart rate or conversion to sinus rhythm due to co-morbidity (IHD, Mitral Stenosis), Direct Current Cardioversion (DCCV) is the treatment of choice. Biphasic external defibrillators are preferred because they are more efficient at successfully cardioverting AF and do so at a lower energy setting. Even with biphasic energy, efficiency is improved if higher energy levels (150J) are used. In practice minimum starting energy should be 100J (200J monophasic) and going up to 200J (360J monophasic).

If initial DCC has failed, loading the patient with 3-5mg/Kg of amiodarone IV will improve the efficacy. However, this increases the risk of severe bradycardia or even cardiac arrest and therefore resuscitation equipment must be available.

Thrombo-embolism is the main risk following cardioversion. Therefore, anticoagulation is mandatory before cardioversion of AF lasting for >48 hour or of unknown duration. These patients should be anticoagulated with warfarin (INR 2-3) for at least 3 weeks. If cardioversion is desired before 3 weeks at the target INR, then trans-oesophageal echocardiography (TOE) must be done to exclude LA thrombus. In this case unfractionated heparin (UFH) or LMWH may be administered before DCC and warfarin started. In patients who have AF, documented to be <48 hours or those needing urgent cardioversion due to haemodynamic instability or other reasons, DCC can be done giving UFH or LMWH before cardioversion. Warfarin should be initiated immediately and heparin continued until target INR levels are achieved. In all cases warfarin should be continued for at least 4 weeks after cardioversion due to the risk of thrombo-embolism because of post-cardioversion left atrial dysfunction. Patients in the category of increased thrombo-embolic risk must continue OAC or NOVACs lifelong.

Post-operative AF

AF commonly occurs after cardiac surgery peaking between day 2 and 4. The incidence is 30% for CABG, 40% after valve surgery and 50% for combined valve surgery and CABG. Pre-operative beta blocker or amiodarone, started at least 1 week before surgery significantly reduced the incidence of post surgical AF ^(6,7,8). In patients who develop AF, rate control is adequate if haemodynamically stable but cardioversion is needed if unstable. Anticoagulation with a VKA should be initiated in all patients with AF > 48 hrs, and continued for 4 weeks after converting to sinus rhythm.

Rhythm or rate control?

The debate of rhythm versus rate control continues. None of the early randomized studies (AFFIRM, RACE, AF-CHF) showed morbidity, mortality, or quality of life benefit of rhythm control over rate control. However, a more recent study (ATHENA)⁽⁹⁾ has shown reduced hospitalization, cardiovascular mortality and stroke, suggesting benefit of maintaining sinus rhythm.



The assessment of quality of life in the early studies is criticized as the instruments used (SF 36 for instance) were tools to measure general quality of life rather than AF symptoms. Quality of life is significantly impaired by AF symptoms and reduced exercise capacity and more recent data show marked improvement in quality of life after achieving SR. A reasonable strategy would be to attempt rhythm control in patients still symptomatic after rate control (class I level B), in young symptomatic patients as a primary strategy, in patients with AF due to secondary triggers which have been corrected (Class IIa level C) and those with heart failure (class IIa level B). In elderly patients with an EHRA score of 1, rate control would be a reasonable option.

Long term management and follow up

Once a patient has been placed in a clinical category a management strategy needs to be planned.

Paroxysmal AF: If the episodes are far apart, short lasting and minimally symptomatic, the patient may opt for no treatment. Patients with more severe symptoms or frequent episodes need either rate or rhythm control. Rate control must always be initiated together with rhythm control for any breakthrough episodes, unless it has been shown that rate is normal during AF. Anticoagulation must be initiated according to CHA₂DS₂VASc score.

Persistent AF: Even if spontaneous conversion to SR occurs or cardioversion is successful, a decision has to be made whether long term strategy is rate or rhythm control. In these patients there is more impetus to attempt rhythm control.

Permanent AF: If a decision has been made to allow AF to be the permanent rhythm, then appropriate rate control and anticoagulation should be initiated. At any time during follow up a decision may be made to convert from rhythm control to rate control or vice-versa. This is also true about initiating or stopping anticoagulation.

Rate control

Earlier studies recommended strict rate control aiming to keep the resting heart rate at 60-80 bpm with an increase to 90-115 bpm with moderate exercise. However recent studies have shown that more lenient control, (resting heart rate <110 bpm) achieves similar symptom control, adverse effects and quality of life while reducing the need for hospital visits ⁽¹⁰⁾.

Drugs commonly used are beta blockers, non-dihydropyridine calcium channel blockers and digoxin. Beta blockers are particularly useful in patients with high sympathetic tone and those with ischaemia. Verapamil and diltiazem are equally effective but should be avoided in patients with systolic dysfunction. Digoxin is effective for rate control at rest but not exertion but can be combined with a beta blocker or calcium channel blocker. Amiodarone is not the first line therapy for rate control but may be needed in addition to a beta blocker or calcium channel blocker in difficult to control patients. Dronedarone, which is still not available in Sri Lanka should not be used in permanent AF for rate control ⁽¹¹⁾.

Rhythm control

Beta blockers and calcium channel blockers are not effective for rhythm control. Studies have shown that amiodarone, propafenone, flecainide and sotalol are all effective with amiodarone being the most efficient. The number of patients needed to treat is 3 with amiodarone, 4 with flecainide, 5 with propafenone, and 8 with sotalol ⁽¹²⁾. Amiodarone and propafenone are the least pro-arrhythmic. Amiodarone is the only drug freely available in Sri Lanka at present. Dronedarone, when available may become a preferred option as though it is not as effective as amiodarone it has a markedly better side effect profile ⁽¹¹⁾.

It is now well established that the origin of non-valvular AF is rapidly firing foci in the pulmonary veins (PVs). Isolation of the PVs from the left atrium by strategically placed lesions using radiofrequency ablation (RFA) or Cryotherapy can be an effective non-pharmacological treatment to achieve rhythm control. This invasive procedure should be considered in patients who remain symptomatic in spite of optimal medical treatment. The procedure is complex and not without complications, some which are serious. Success is greater in patients in the early stages of PAF, without LA dilatation, significant mitral valve disease or LVH. The clinical benefits include abolishing of AF, reducing AF burden and need for anti-arrhythmic drugs and significantly improving symptoms and quality of life, but more than one procedure may be needed for satisfactory outcome ⁽¹³⁾. The procedure is at present not freely available in Sri Lanka due to limited access to necessary equipment and demand for the treatment of other arrhythmias in the few Electrophysiology centers in the country.



Pacing and AV node ablation

Permanent pacing may be needed in patients with very slow ventricular rates during AF or those who have those with sick sinus syndrome and alternating AF and bradycardia. Those patients with severe symptoms and where rate or rhythm control cannot be achieved, and who are not suitable or have unsuccessful RF procedures will also benefit from pacing. In these situations, once the pacemaker is implanted an AV node ablation is done creating AV dissociation. This generally provides significant symptomatic relief but is done as a last resort procedure as it is irreversible.

Surgical procedures

The surgical maze, a cut and sew procedure in the LA is very successful in terminating and maintaining sinus rhythm but is too invasive with a significant mortality risk. It cannot be recommended as a standalone procedure though as part of other cardiac surgery (MV replacement etc.) it could be considered though significant complications still occur. A hybrid procedure using RF energy to create a maze is a much safer and viable option, especially as an adjuvant to MV surgery ⁽¹⁴⁾.

Adjuvant therapy

ACE inhibitors and ARBs

There is some evidence that ACEIs and ARBs reduce the incidence of AF in patients with LV dysfunction and LVH though the evidence is not robust. It would be logical to use either in a setting of hypertension or LV dysfunction.

Statins

There is some evidence that statins may prevent onset of AF after ischaemic events or after cardiac surgery. The evidence is slim to support statins in the secondary prevention of AF but given the demographics of hyperlipidaemia in our region it is likely that many patients will need statins and may benefit from whatever effect it will have on AF.

Follow up

Once initial management has been done it is important to plan the follow up. The following are important considerations for follow up which may change the management strategy.

- Need for anticoagulation – the need for initiating anticoagulation if risk profile has changed (new diabetes or hypertension or recent TIA). Alternatively, the need for anticoagulation may have passed (post cardioversion) or patient may need modification of anticoagulation for other purposes (surgery).
- Symptoms – Has the patients symptoms improved, in which case medications may be reduced. Is there adequate rhythm or rate control. Does the patient have symptoms suggesting pro-arrhythmia or side effects of drugs?
- Change in classification – has a paroxysmal AF changed to persistent AF or to permanent. In this case it may be necessary to change medication or take a decision about cardioversion.

Summary

In conclusion, a stepwise approach to the management of AF is needed to provide the best outcome for the patient. Treatment needs to be tailored for the individual and needs to be reviewed regularly as patient's AF and anticoagulation status can change.

References

1. Stewart S, Hart CL, Hole DJ, McMurray JJ. Population prevalence, incidence, and predictors of atrial fibrillation in the Renfrew/Paisley study. *Heart* 2001;86:516-521
2. Kirchhof P, Auricchio A, Bax J, et al. Outcome parameters for trials in atrial fibrillation: executive summary. Recommendations from a consensus conference organized by the German Atrial Fibrillation Competence NETwork (AFNET) and the European Heart Rhythm Association (EHRA). *European Heart Journal* 2007;28:2803–2817.



Review

3. Camm AJ, Kirchhof P, Lip GY et al. the Task Force for the Management of Atrial Fibrillation of the European Society of Cardiology Guidelines for the management of atrial fibrillation. *European Heart Journal* 2010; 31(19): 2369-2429
4. Brian F. Gage, Carl van Walraven, Lesly Pearce, et al. Selecting Patients with Atrial Fibrillation for Anticoagulation. *Circulation*. 2004;110:2287-2292.
5. Pisters R, Lane DA, Nieuwlaat R, de Vos CB, Crijns HJ, Lip GY. A novel user friendly score (HAS-BLED) to assess one-year risk of major bleeding in atrial fibrillation patients: The European Heart Survey. *Chest* 2010; March 18 [Epub ahead of print].
6. Crystal E, Garfinkle MS, Connolly SS, Ginger TT, Sleik K, Yusuf SS. Interventions for preventing post-operative atrial fibrillation in patients undergoing heart surgery. *Cochrane Database Syst Rev* 2004;4:CD003611.
7. Burgess DC, Kilborn MJ, Keech AC. Interventions for prevention of postoperative atrial fibrillation and its complications after cardiac surgery: a meta-analysis. *European Heart Journal* 2006;27:2846–2857.
8. Bagshaw SM, Galbraith PD, Mitchell LB, Sauve R, Exner DV, Ghali WA. Prophylactic amiodarone for prevention of atrial fibrillation after cardiac surgery: a meta-analysis. *Annals of Thoracic Surgery* 2006;82:1927–1937.
9. Stefan H. Hohnloser, M.D., Harry J.G.M. Crijns, M.D., Martin van Eickels, M.D., et al. for the ATHENA Investigators. Effect of Dronedarone on Cardiovascular Events in Atrial Fibrillation. *New England Journal of Medicine* 2009; 360:668-678.
10. Van Gelder IC, Groenveld HF, Crijns HJ et al. Lenient versus strict rate control in patients with atrial fibrillation. *New England Journal of Medicine* 2010;362:1363–1373.
11. Singh BN, Connolly SJ, Crijns HJ, et al. Dronedarone for maintenance of sinus rhythm in atrial fibrillation or flutter. *New England Journal of Medicine* 2007;357:987–999.
12. Lafuente-Lafuente C, Mouly S, Longas-Tejero MA, Bergmann JF. Antiarrhythmics for maintaining sinus rhythm after cardioversion of atrial fibrillation. *Cochrane Database Syst Rev* 2007;4:CD005049.
13. Rohan Gunawardena, Stephen S Furniss, Ewan Shepherd, Giuseppe Santarpia, Stephen W Lord, John P Bourke. Outcomes Following Catheter Ablation of Atrial Fibrillation in the UK – A Single-centre Cohort Analysis *British Journal of Cardiology* 2010;17:271–276.
14. Melby SJ, Zierer A, Bailey MS, et al. A new era in the surgical treatment of atrial fibrillation: the impact of ablation technology and lesion set on procedural efficacy. *Annals of Surgery* 2006; 244:583-592.



Research

Malnutrition in Children with Congenital Heart Disease - is it a concern?

HMSL Jayasekara¹, TG Samarasekara¹, SN Perera¹, Renuka Jayatissa², KH De Silva²

1. Lady Ridgeway Hospital for Children Sri Lanka

2. Department of Nutrition, Medical Research Institute, Sri Lanka

Corresponding Author: Dr. G. Samarasekara

Email: gowrisamarasekera@gmail.com

Abstract

The incidence of congenital heart disease (CHD) is approximately 8 in every 1000 live births worldwide. Malnutrition and growth retardation are associated with complex CHD in infancy and childhood. Objective of this study was to determine the prevalence of malnutrition among children born with congenital heart disease attending a tertiary care cardiology unit.

All CHD children admitted to the cardiology unit at Lady Ridgeway hospital during December 2018 were included. Type of the cardiac lesion (cyanotic/acyanotic), birth-weight were obtained from the patient's records. Weight and length/ height were measured, and WHO standards were used to assess nutritional status.

A total of 39 children were recruited; 25 infants, 9 children aged 1-5 years and 5 children >5 years. Mean age was 20.6 (27.1) months, two third were females and 64% were acyanotic. Commonest CHD was VSD. Among them, prevalence of severe wasting, severe stunting and low birth weight (LBW) were 25.6, 30.1 and 25.6 percent respectively. Wasting was significantly higher ($p < 0.05$) in children with acyanotic heart disease (65.7%) compared to children with cyanotic heart disease (30.4%).

Half of children with CHD had acute malnutrition. Focus on nutrition therapy is important routinely to improve the outcome of CHD children.

Keywords: Congenital heart disease, malnutrition, stunting, wasting

Introduction

The Congenital Heart Disease (CHD) is the commonest congenital anomaly occurring approximately 8 in every 1000 live births worldwide ⁽¹⁾. Though there are several lesions in the heart, eight lesions make up 80% of cases, the most common of which are Ventricular Septal Defect (VSD), Patent Ductus Arteriosus (PDA), Atrial Septal Defect (ASD) and Tetralogy of Fallot (TOF) ⁽¹⁾. Though the new advances in medical and surgical management have resulted in good clinical outcomes, growth failure and nutritional deficiencies are common among children with CHD which have adverse clinical outcomes as recurrent pre-operative infection rates, increased post-operative infection rates and hospital stay ⁽²⁾.

Nutritional impairment and hence poor growth is common among children with CHD. Children with CHD experience growth failure during the first few months of life even though most of them had normal birth weights ⁽³⁾. The prevalence of moderate malnutrition (defined as weight for age between -2SD to -3SD) among infants with CHD is between 21 and 29% ⁽⁴⁾.

When we consider the pathophysiology of CHD, children with cyanotic lesions appear to be having the greatest risk of stunting, may be due to chronic suboptimal tissue oxygenation reducing the linear growth ⁽⁵⁾.

But the children with complex acyanotic heart diseases are more prone to develop wasting, may be due to pulmonary hypertension ⁽⁵⁾. Children with complex cardiac defects complicated with cyanosis as well as pulmonary hypertension are at the greatest risk of a combination of both stunting and wasting ⁽⁶⁾.

Children with pulmonary hypertension with cyanosis may have very limited nutrient intakes compared to pulmonary hypertension or cyanosis alone ⁽⁹⁾. In addition, children with complex lesions need palliative surgery, or a staged rather than single repair, may be at higher risk of poor growth, which require a close monitoring. It is therefore important to correct nutritional deficits prior to surgery to minimize post-surgical risk of complications. Fatigue on feeding leading to low total nutrient intake, early satiety, anorexia, vomiting, frequent infections and frequent use of antibiotics affecting gut flora are the other additional factors involving in malnutrition.

Apart from above mentioned factors, raised energy expenditure also contributes to poor growth ⁽¹⁰⁾.

Therefore nutrition intervention is mandatory preoperatively to enhance immune response and functional reserve.

Ultimately it will reduce the length of hospital stay and thereby Intensive Care Unit (ICU) cost.



The final outcome of nutritional optimization is to reduce morbidity and mortality.

In Sri Lanka, malnutrition and failure to thrive is observed in infants and children with CHDs at clinical settings. But published data is scarce. Hence this study was conducted to assess the prevalence and associated factors of malnutrition in children with CHDs.

Methodology

This is a descriptive cross-sectional hospital based study. Study population was children aged 0-8 years admitted to the cardiology unit of Lady Ridgeway Hospital for children (LRH), which is the largest children's hospital in Sri Lanka. The study was conducted in December 2018.

All the children with CHD who were admitted during the study period was included in the study. After obtaining the consent from the mother or caretaker, information was gathered on age, sex and birth weight from the Child Health Development Records (CHDR).

Type of the cardiac lesion, cyanotic or acyanotic and stage was obtained from the patient's record.

Weight and height or length was measured using stadiometer and electronic weighing scale by a trained measurer adopting WHO protocol.

Anthro and Anthro-plus software was used to analyze the anthropometric data (WHO 2005, 2009). Severe wasting and wasting were defined as weight-for-height $< -3SD$ and $< -2SD$ for children below 5 years and BMI-for-age $< -3SD$ and $< -2SD$ for children above 5 years respectively. Severe stunting and stunting were defined as height-for-age $< -3SD$ and $< -2SD$ respectively. Data was analyzed using SPSS software package version 24.

Results

A total of 39 children with CHD was recruited. Table 1 shows majority of children were below five years of age (82%), females (69.2%) and 64.1% had acyanotic heart diseases.

Table 2 shows the prevalence of malnutrition of the study population namely stunting and wasting. The prevalence of severe stunting is 25.6% in the study population. About 30% of children were severely wasted while half (51.6%) of children were wasted.

Table 1: Basic characteristics of study

Characteristics	No (%)
Age categories in months	
< 12	25 (64.1)
12 - 59	9 (17.9)
≥ 60	5 (17.9)
Mean age \pm SD	20.6 \pm 27.1
Range	1 - 96 months
Sex	
Male	12 (30.8)
Female	27 (69.2)
Stage of CHD	
Cyanotic	14 (35.9)
Acyanotic	25 (64.1)
Type of CHD	
VSD	11 (28.2)
TOF	9 (23.1)
PDA	6 (15.4)
IAS	3 (7.7)
Transposition of great arteries	3 (7.7)
Many lesions	5 (12.8)
Birth weight in kg	
< 2.5	10 (25.6)
≥ 2.5	29 (74.4)
Mean birthweight \pm SD	2.8 \pm 0.5
Range	1.8 - 3.7



Table 2: Prevalence (%) of malnutrition of the study population

Anthropometric indicators	Severe < -3SD	Moderate and severe < -2SD	Other ≥ 2SD
Stunting (Chronic malnutrition)	25.6	46.2	53.8
Wasting (Acute malnutrition)	30.1	51.6	48.4

Table 3: Prevalence (%) of malnutrition of the study population in relation to basic characteristics

Basic characteristics	Stunting (height-for-age <-2SD)		Wasting (weight-for-height <-2SD)	
	Yes	No	Yes	No
Age in months				
< 12	48.0	52.0	60.0	40.0
12 - 59	33.3	66.7	37.5	62.5
≥ 60	60.6	40.0	20.0	80.0
Sex				
Male	58.3	40.7	62.5	37.5
Female	40.7	59.3	47.9	52.1
Stage of CHD				
Cyanotic	42.9	57.1	30.4	69.6
Acyanotic	48.0	52.0	*65.7	34.3
Type of CHD				
VSD	45.5	54.5	*86.4	13.6
TOF	44.4	55.6	30.9	69.1
PDA	33.3	66.7	55.0	45.0
Others	53.8	46.2	35.4	64.6
Birth weight in kg				
< 2.5	60.0	40.0	66.9	33.1
≥ 2.5	41.4	58.6	49.9	50.1
Total	46.2	53.8	51.6	48.4

*(P<0.05)

48% of children under 1 year were stunted while 60 % of children were wasted as shown in Table 3. One third of children between 12 to 59 months were stunted and wasted while 60% of children more than 5 years were stunted.

Male or female gender did not show any significant association with wasting and stunting.

Similar prevalence of stunting was observed among children with acyanotic heart diseases (48%) compared to children with cyanotic heart diseases (42.9%).

Wasting was significantly higher (p<0.05) in children with acyanotic heart disease (65.7%) compared to children with cyanotic heart disease (30.4%).



The children with LBW had higher prevalence of stunting (60% Vs 41.4%) compared to children born with a birth weight above 2.5 kg though it was not significant. Wasting was higher among children with LBW compared to children with normal birth weight (66.9 vs. 49.9%).

Discussion

Malnutrition is more common among children with congenital heart disease due to difficulties in establishing total energy requirement with restricted fluid intake during the neonatal period. Apart from the increased energy requirements with increased cardiac workload, recurrent respiratory tract infections, and difficulties in supplying energy requirements with complementary feeding and frequent recurrent hospital admissions are other concerns ⁽¹⁴⁾.

Our study has shown that the severe malnutrition among children with CHD is 30.1%, which is much higher when compared with available national data which is 3.0% ⁽¹²⁾. The children included in our study were admitted to the ward awaiting cardiac surgery. Most of them had been on the waiting list for several months due to lack of facilities which may be the main reason for inadequate calorie intake with multiple co factors such as maternal anxiety, lack of frequent visits due to far away home towns, economic problems, lack of facilities to prepare meals, lack of play areas and minimum sun exposure. Apart from inadequate caloric intake, malabsorption, and increased energy requirements caused by increased metabolism may also contribute to malnutrition. However, inadequate caloric intake appears to be the most important cause of growth failure in CHD. Optimizing nutritional status improves surgical outcome and contributes to reduced morbidity and mortality.

Significantly higher prevalence (65.7%) of wasting among acyanotic heart disease children could be due to increased physical activity compared to children with cyanotic heart disease ⁽⁴⁾. Children with cyanotic heart disease are prone to develop more complications leading to limited physical activity and reduced mobility therefore less energy requirement with less under nutrition. In contrast to that, children with acyanotic heart disease are active with increased energy requirements as well as with increased susceptibility to infections ⁽¹³⁾.

The national prevalence of stunting is 17.3%, which is lower than the stunting prevalence (46.2%) in our study ⁽¹²⁾. Childhood stunting can have long term effects on cognitive development, school achievements and economic productivity in adulthood and maternal reproductive outcomes ⁽¹¹⁾.

Ultimately this will lead to reduced productivity in future in Sri Lanka. But there is no significant difference of prevalence of stunting among cyanotic or acyanotic heart disease ($p = 0.697$).

These facts highlight the importance of early intervention to prevent malnutrition among children with congenital heart disease. Early surgical intervention as well as effective and early nutritional interventions are important for prevention and slowing down of development of malnutrition. As first thousand days are important for optimum growth and development of every child, importance of earliest possible interventions is highlighted with the results.

There is increased morbidity and mortality among low birth weight infants with congenital heart disease compared to normal population ⁽³⁾. The prevalence of low birth weight among live births in Sri Lanka is 15.7% while prevalence of low birth weight is higher (25.6%) among study population ⁽¹²⁾.

Malnutrition in children with CHD leads to a vicious cycle which will worsen both malnutrition and complications of CHD which can be corrected by, with earliest possible, optimum and individualized interventions.

The results could be different with a larger sample which needs further research. Disease categorization could be more precise if presence of pulmonary hypertension is also included.

Conclusion

Prevalence of acute and chronic malnutrition is higher among children with CHD with higher numbers from acyanotic heart disease. Further research is needed with extensive disease categorization to identify reasons for malnutrition and associated factors of malnutrition to improve the outcome. There is an urgent need to provide nutrition therapy for these children and advice to the parents/guardians.



References

1. Noonan J Noonan syndrome and related disorders. *Progress Pediatr Cardiol*, 2005, 20177-8.
2. Wynn Cameron J, Rosenthal MD, Olson AD Malnutrition in hospitalized children with congenital heart disease. *Arch Pediatr Adolesc Med*, 1995, 149: 1098-102.
3. Jacobs EGJ, Leung MP, Karlberg JP Postnatal growth in southern Chinese children with symptomatic congenital heart disease. *J Pediatr Endocrinol Metab*, 2000, 11195-202.
4. Varan B, Tokel K, Yilmaz G. Malnutrition and growth failure in cyanotic and acyanotic congenital heart disease with and without pulmonary hypertension. *Archives of Disease in Childhood*, 1999 Jul 1; 81(1): 49-52.
5. Waterlow JC Protein Energy Malnutrition. London: Edward Arnold, 1992: 231-2.
6. Farrell AG, Schamberger MS, Olson IL, Leitch CA Large left-to-right shunts and congestive heart failure increase total energy expenditure in infants with ventricular septal defect. *Am J Cardiol*, 2001; 871128-31.
7. Barton J, Hindmarsh P, Scrimgeour C. et al. Energy expenditure in congenital heart disease. *Arch Dis Child*, 1994; 705-9.
8. Ocal B, Unal S, Zorlu P. et al. D Echocardiographic evaluation of cardiac function and left ventricular mass in children with malnutrition. *J Paediatr Child Health*, 2001, 3714-17.
9. Soliman A, Madkour A, Abdel Galil M et al. Growth parameters and endocrine function in relation to echocardiographic parameters in children with ventricular septal defect without heart failure. *J Trop Pediatr*, 2001; 47146-52.
10. Thommessen M, Heiberg A, Kase B Feeding problems in children with congenital heart disease: the impact on energy intake and growth outcome. *Eur J Clin Nutr*, 1992; 46457-64.
11. Kathryn G. Dewey and Khadija Begum, Long-term consequences of stunting in early life. *Maternal and Child Nutrition* 2011; 7(Suppl. 3): 5-18.
12. Department of Census and Statistics. *Demographic and Health Survey 2016*. Government of Sri Lanka. Colombo. 2017.
13. Pujitha Wickramasinghe SPL and SN. Prospective study of congenital heart disease in children. *Ceylon Medical Journal*, 2000; 96-8.
14. M.P. Gamage, K. Sithamparapillai, S.N. Perera, Randula Ranawaka, Renuka Jayatissa, Prevalence of malnutrition in children with Congenital Heart Disease awaiting cardiac interventions at a tertiary care setting in Sri Lanka. *Sri Lankan Journal of Cardiology*, January 2019; 1(2): 39-43.



Research

Effect of Anticoagulation on the Lifestyle in Sri Lankan patients with Mechanical Valves - Prevalence of Nonfatal Complications of Anticoagulation and the Episodes of deranged INR among the followed up patients with Mechanical Prosthetic Heart Valves

Palinda Bandarage¹, Mahendra Munasinghe²

1. Specialist registrar, Cardiothoracic Surgery, Oxford University Hospital, UK

2. Department of Cardiothoracic Surgery, National Hospital of Sri Lanka.

Corresponding Author: Dr. M Munasinghe, Consultant Cardiothoracic Surgeon

Email: munasinghem@yahoo.com

Abstract

While mechanical valve prosthesis remains the ideal choice for valve replacement where longevity is concerned, the mandatory anticoagulation with warfarin leaves such patients at risk of haemorrhagic and thrombotic complications. This affects the patient's lifestyle and is a burden to the health services. Although the long-term outcome of oral anticoagulation in valve patients is a common topic in international literature, studies in Sri Lankan patient population is scarce. This was a retrospective observational study including all the patients who were being followed up following mechanical valve replacement between January 2010 and December 2014 in a cardiac surgical unit in the National Hospital of Sri Lanka. A total of 148 patients were followed up. A significant number of patients had hospital admissions with deranged INR having variable durations of stay. Overall complication rates were less compared with the literature, possibly explained by the fact that untraceable and deceased patients could not be included in the study. A more robust follow up and incident reporting system would be beneficial to improve the situation.

Keywords: Anti Coagulation, INR, Mechanical valves

Introduction

While the surgical management of valvular heart disease is increasingly popular globally, it has become reasonably accessible now in low income countries as well. With the technological advances in this respect, the immediate outcome and patient survival rate over the decades have dramatically improved, but life-long anti-coagulation therapy remains mandatory for all mechanical valve prostheses. Hence it is inevitable that we have to face the challenges of long-term anticoagulation that brings its own complications, mainly haemorrhagic or thrombotic. Although the anticoagulation therapy carries a high burden on the patient, detailed studies/research in to the situation in Sri Lankan patients are scarce. This study was designed with the intention of identifying the frequency of complications associated with mechanical prosthetic valves among the patients who present for follow up and are on long-term anticoagulation.

Literature review

Worldwide, the overall outcome of cardiac valve replacement surgery has improved with the 10 year survival reaching above 60% even among most high risk patient groups. Nonetheless, the associated morbidity due to valve related complications remains significant. Thromboembolism, haemorrhagic episodes and prosthetic valve endocarditis are the common complications associated with the prosthetic valves and the mandatory anticoagulation therapy⁽¹⁾

While the mechanical cardiac prosthetic valves unlike bioprosthetic valves have the advantage of outliving the patient with no need of redo surgery, being on lifelong anticoagulation is essential to prevent thrombus formation on the valve's surface. Although there are novel oral anticoagulants used for other conditions these are not currently indicated for the use for anticoagulation of patients with mechanical valves⁽²⁾.

Though it is a necessity for the patient to take oral anticoagulants uninterrupted, the complex pharmacokinetics and the wide array of interactions sometimes make it a difficult task to maintain a stable International normalized ratio INR⁽³⁾. While sub-therapeutic anticoagulation with low INR can lead to thromboembolic complications, excessive anticoagulation can cause haemorrhages⁽⁴⁾. Both these complications increase the morbidity and mortality of the condition. Furthermore very regular checking of INR with dose adjustments and management of sub or supra therapeutic levels of the anticoagulant is a burden the patients with mechanical valves have to face⁽⁵⁾.

Currently, according to international literature the average prevalence of overall valve related complications stands at 0.7% to 3.5% per patient years^(1,6). Out of this, thrombosis associated valve complications were seen at a rate of nearly 1% per patient year and prevalence of haemorrhagic complications were approximately 0.5% per patient year.

**Table 1: Approximate prevalence of mechanical valve related complications ⁽¹⁾**

	All valve related complications	Thromboembolic complications	Haemorrhagic complications
% per patient year	0.7 – 3.5	Approximately 1.0	< 0.5

In a study which followed up 440 patients with St Jude mechanical valve implantation in the mitral position for 19 years it was found that thromboembolic and haemorrhagic complications were 0.7% and 1% patient-years respectively ⁽⁷⁾.

The valve type, its position, and co existing cardiac factors such as the atrial dilatation, atrial fibrillation increase the risk of major valve associated complications. Furthermore good patient compliance with regular assessment of INR levels and optimizing of the warfarin dose is essential. On the other hand warfarin being a drug with many interactions including a number of food items and drugs, demands optimum patient compliance to maintain the anticoagulation in the desired range ⁽³⁾. Considering all these intricacies, in the current era, use of novel oral anticoagulants may benefit Sri Lankan patients.

A similar study done in the Indian setting showed that a statistically significant wide variation in INR among patients with combined aortic and mitral valve replacements and isolated AVR, leading to high risk of thromboembolic and haemorrhagic complications ⁽⁸⁾.

Methods

This was a retrospective, observational study in which the study population included all the patients who underwent mechanical valve replacement between January 2010 and December 2014 and were scheduled for long-term clinic follow up at the National Hospital Cardiothoracic clinic.

Patients who underwent valve repair and patients who had bioprosthetic valve replacements were excluded. Similarly patients who underwent mechanical valve replacement but opted to get followed up in their local hospital clinics and patients who defaulted anticoagulation therapy were excluded.

Data were collected using an interviewer administered questionnaire at the clinic visit.

Results

There were 148 patients with mechanical heart valves that were followed up in the clinic within the duration planned to be studied accounting for 888 total patient years.

Mean number of admissions for INR correction per patient year was 0.74 while the mean number of days per patient year spent inward for INR correction was 4.44. The exact number of admissions and number of days spent in ward were highly variable and varied between 0 to 4 admissions and 0 and 14 days per year respectively.

There were 24 patients who developed haemorrhagic episodes, implying a rate of 0.451 haemorrhagic episodes per 10 patient years. Furthermore 4 patients developed thromboembolic episodes amounting to 0.045 per patient year. The rate of total neurological complications per 10 patient years was 0.136.

Type of valve prosthesis	Aortic - 58	Mitral - 80
Gender	Male - 68	Female - 80
Employment	Employed - 67	Unemployed - 81
Age at surgery	< 50 yrs - 62	> 50 yrs - 86



Conclusion

The number of admissions to ward and the time spent in ward were highly variable while some patients had a high frequency of admissions and longer hospital stays.

The rate of both haemorrhagic and thrombotic complications seen were significant but were lower, when compared to most of the studies in similar settings found in the literature.

Discussion

It is notable that the complication rate reported in the study was low compared to most parallel studies in the literature ^(1,3,6). Although strict regular follow up with timely assessment of INR is a must in all patients with mechanical prosthetic valves, a significant proportion of patients fail to follow this rule due to various reasons ⁽⁶⁾. The population recruited for the study was the total number of patients who voluntarily presented for regular follow up in the same hospital they underwent valve replacement. Although this included the majority of the post-operative patient population it did not include the patients who opted to get followed up in the local hospital haematology clinics for convenience.

The identification and quantification of the exact number of defaulted patients were practically impossible due to this reason. This fact highlights the need of a robust follow up and reporting mechanism where defaulters can be approached by a community health staff officer ⁽⁹⁾.

The number of admissions was significantly high in the study population with a wide individual variation. Although parallel results were not available in the literature to compare how the derangements in INR and subsequent hospital admissions affect the lifestyle and employment of patients it is the belief of the research team that measures to stabilize the INR and ensure regular follow ups will increase the quality of life in these patients. Furthermore, a drawback in the study is failure to consider the fatal complications among followed up cases.

This holds true for any system lacking proper community follow up such as ours.

Hence the rate of complications will be misleading as any fatalities among the clinic patients and complications of any degree among patients lost to follow up had to be exempted from the study due to practical reasons.

One key fact that facilitates smooth management of anticoagulation therapy is the patient's knowledge regarding the treatment and the vigilant identification of early signs of haemorrhage or thrombosis. As warfarin has a narrow therapeutic window with a number of drug to drug and drug to food interactions, counselling and regular updating is vital ⁽¹⁰⁾. This is definitely an area for improvement in the local setting.

In conclusion the population of patients presenting for follow up had minimal complications compared to the international average but some had to undergo significant durations of in ward treatment for correction of deranged INR. Avoiding mechanical valves by repairing the valves whenever possible and using newer generation valves with lesser need of anticoagulation are prospective options, which would have a positive impact.

References

1. Misawa Y. Valve - related complications after mechanical heart valve implantation. *Surg Today [Internet]*. 2015;1205-9. Available from: <http://dx.doi.org/10.1007/s00595-014-1104-0>
2. Aimo, A., Giugliano, R. P. & DC. Non - Non-Vitamin K Antagonist Oral anticoagulants for Mechanical Heart Valves. *Circulation*. 2018; **138**(13):1356-65.
3. Labaf A, Grzymala-lubanski B, Stagmo M, Lövdahl S, Wieloch M, Sjölander A, et al. Thromboembolism, major bleeding and mortality in patients with mechanical heart valves- a population-based cohort study. *Thromb Res [Internet]*. 2014; **134**(2): 354-9. Available from: <http://dx.doi.org/10.1016/j.thromres.2014.06.00>.
4. Kratz JM, Iii AJC, Stroud MR, Bradley SM, Sade RM, Crawford FA. Twenty-year experience with the St Jude Medical mechanical valve prosthesis. 2003 (December).
5. Kandemir O, Tokmakoglu H, Yildiz U, et al. St. Jude Medical and CarboMedics mechanical heart valves in the aortic position: Comparison of long-term results. *Texas Hear Inst J*, 2006; **33**(2): 154-9.



6. Canicelli A. Anticoagulation for Valvular Heart Disease - American College of Cardiology. Am Coll Cardiol. May 2015.
7. Despins P, Michaud JL, Duveau D. Isolated Mitral Valve Replacement With St Jude Medical Prosthesis. 2001; (Table 1): 1542-5.
8. Ujjwal K Chowdhury, Pranav Sharma, Lakshmi Kumari Sankhyan, et al. Annals of Short Reports Thromboembolic and Bleeding Complications following St Jude's valve replacement. Rem Publ. 2018; 1(2): 1009.
9. Jaffer A, Bragg LEE. Practical tips for warfarin. 2003; 70(4): 361-71.
10. Kuruvilla M G-TC. Pharmacology NNotes. Proc (Bayl Univ Med Cent). 2001; 75246: 305-6.



Updates

COVID -19 Practice Points and Updates for Cardiologists

G Reshmaal Gomes Cumararatunge¹

1. Consultant Cardiologist, Phoenix, Arizona, USA

Corresponding author: E-mail: reshygomesmd@phoenixheart.com

Introduction

Physicians have been impacted by the 2019 novel coronavirus, or severe acute respiratory syndrome coronavirus-2 (SARS-CoV-2) that results in coronavirus disease-2019 (COVID-19), irrespective of where they trained or where they practice currently. We were all bombarded with treatment options on a daily basis. What was thought to be Best Practice in February 2020 may well not be so today.

So how do we navigate through this myriad of information?

Below are some practice points and updates compiled from recent recommendations from American College of Cardiology and local practice here in Arizona as of June 20th 2020.

How should Acute Myocardial Infarction be managed during COVID-19? ⁽¹⁾

COVID-19 patients are complex: patients may present with acute myocardial infarction (AMI), myocarditis simulating a STEMI, stress cardiomyopathy, nonischemic cardiomyopathy, coronary spasm, or myocardial injury without a documented Type I or Type II AMI, requiring careful diagnostic differentiation to maximize therapeutic effectiveness and minimize unnecessary medical staff exposure risk.

Nonetheless, most AMI cases remain COVID negative and should be managed aiming at expedient revascularization according to standard PCI protocols.

Fibrinolysis-based reperfusion strategy may be appropriate in non-PCI capable hospitals, especially when timely transfer is not practical, or when otherwise clinically indicated.

AMI standard-of-care during COVID-19: All efforts should be made to maintain the current AMI standard-of-care.

Door-to-balloon times remain important and should continue to be measured; however, additional time may be required for careful clinical differentiation of both COVID status and precise MI etiology to minimize exposure risk and ensure the appropriate therapeutic intervention.

AMI management protocols in the context of pandemic COVID-19 should be developed in advance, and include ambulance/EMS, the Emergency room and the cardiac catheterization laboratory (CCC). Dedicated COVID-19 CCLs and PPE should be available in geographies with widespread community transmission.

- **Definite STEMI:** Primary PCI within 90 minutes remains the standard-of-care in PCI capable hospitals regardless of COVID status. Additional exposure precautions are mandatory in probable and confirmed COVID-19 patients, but may be considered for all cases given asymptomatic presentation and the potential for false-negative COVID test results.
- **Possible STEMI:** For patients who have an unclear, or equivocal, diagnosis of STEMI due to atypical symptoms, diffuse ST-segment elevation or atypical ECG findings, or a delayed presentation, additional noninvasive evaluation is recommended.
- **Futile prognosis:** Not all COVID-19 patients with ST elevation with/without an acute coronary occlusion will benefit from any reperfusion strategy or advanced mechanical support.
- **In COVID-19 confirmed patients with severe pulmonary decompensation (adult respiratory distress syndrome) or pneumonia who are intubated in the ICU and felt to have an excessively high mortality, consideration for compassionate medical care may be appropriate.**



- *Non -STEMI capable referral hospitals:* Primary PCI remains the standard of care for patients transferred rapidly from non-PCI centers (within 120 minutes of first medical contact at Referral Hospital).
- For patients in whom rapid reperfusion with primary PCI is not feasible, a pharmacoinvasive approach is recommended with initial fibrinolysis followed by consideration of transfer to a PCI center.
- The COVID status of the individual patient, along with the COVID burden at both the referring and receiving hospital may require modifications to this standard.
- *Cardiogenic shock and/or out-of-hospital cardiac arrest:* Patients with resuscitated out-of-hospital cardiac arrest (OHCA) and/or cardiogenic shock will continue to be the highest risk subgroup of AMI patients.
- These patients will also be the highest risk for droplet-based spread of COVID-19. Patients with resuscitated OHCA should be selectively considered for CCL activation in the presence of persistent ST-elevation on their electrocardiogram, and a concomitant wall motion abnormality on echocardiographic evaluation.
- *Non-ST elevation AMI:* (Standard of care to both COVID positive and negative patients):- COVID-19 positive or probable patients with an NSTEMI presentation should be managed medically and only taken for urgent coronary angiography and possible PCI in the presence of high-risk clinical features (Global Registry of Acute Coronary Events [GRACE] score >140) or hemodynamic instability.

What are the considerations for cardiomyopathy and heart failure in COVID-19? ⁽²⁾

Cardiac dysfunction is moderately common among hospitalized patients with COVID-19 and confers a worse prognosis; focused imaging and other cardiac diagnostics are warranted to guide differential management, but must be balanced against exposure risk; clinical management remains supportive although experimental strategies are being evaluated.

Cardiomyopathy has been described in patients with severe COVID-19 disease and increasing evidence suggests that cardiovascular involvement portends a high mortality. Viral infection with SARS-CoV-2, the causative agent of COVID-19, has been proposed to impact cardiac function via at least three distinct mechanisms.

First, the later phase of COVID-19 disease is associated with a profound systemic inflammatory response. The cytokines released during this phase have the potential to trigger cardiomyocyte dysfunction and cardiac depression.

This phenomenon has been well described in other inflammatory conditions such as sepsis, where $\text{TNF}\alpha$ and $\text{IL-1}\beta/\beta$ directly suppress cardiomyocyte contractility.

Second, SARS-CoV-2 can directly infect the heart leading to immune cell recruitment and myocarditis. To date, there are few data from patients with COVID-19 to gauge the exact frequency of myocarditis. However, the heart expresses the SARS-CoV-2 receptor ACE2 and MRI-based imaging and ECG findings of myocardial involvement have been reported^(2,3).

In addition, a study of the related virus SARS-CoV-1, which also uses ACE2 for cell entry, demonstrated the presence of viral RNA in 35% of hearts at autopsy. Interestingly, cardiac tissue from patients with positive viral RNA had an increase in macrophage infiltration, but not a substantial T-cell response.

Third, infection with SARS-CoV-2 could impact the microvasculature via its effects on ACE2. This could trigger microvascular dysfunction and tissue ischemia leading to ventricular dysfunction and/or arrhythmias.

Ongoing investigation and further autopsy studies will be necessary to determine the proportion of patients with secondary vs. primary cardiac involvement. Those with underlying cardiovascular disease are particularly vulnerable to the cardiac effects of COVID-19-induced inflammation.

In severe COVID-19 cases, cardiomyopathy may result from SARS-CoV-2-induced myocarditis, profound systemic inflammation, and/or microvascular dysfunction.



There is currently very little data to guide the optimal management of patients with COVID-19 disease who develop cardiomyopathy or mixed/cardiogenic shock.

Cardiac imaging may be useful, but only when testing is likely to result in differential management and exposure risk can be adequately mitigated.

- In patients hospitalized with COVID-19 cardiac biomarkers (troponin and natriuretic peptide levels) should be checked on admission and in follow-up approximately 24-48 hours later. Increased troponin and natriuretic peptide levels have a worse prognosis.
- Myocarditis or inflammatory cardiac dysfunction should be considered in patients with COVID-19 who have elevated cardiac biomarkers and worsening hemodynamics or arrhythmias.
- ECG should be employed to screen for evidence of ST-T wave changes can include diffuse ST-elevations as seen in myopericarditis, nonspecific ST changes, low voltage in the limb leads, and PVCs. Patients can also present with STEMI in the setting of COVID-19 and often without evidence of coronary obstruction, perhaps secondary to myocarditis or direct cardiac injury from the virus.
- Maintain a low threshold for point of care ultrasound (POCUS) in patients with the above clinical features.
- If evidence of cardiac dysfunction, select view for transthoracic echocardiography (TTE) to define LV/RV size and function, wall motion abnormalities, and/or pericardial effusion. In most cases, a limited study can provide the necessary information for medical decision-making.
- Stable patients with suspected cardiovascular involvement should continue on guideline-directed medical therapy for heart failure.
- In patients with refractory shock, consider pulmonary artery catheters to help guide the use of inotropes, vasopressors or mechanical support.

- Endomyocardial biopsy may have a role in select patients being considered for clinical trials of anti-inflammatory therapy.

Management of Cardiomyopathy in COVID-19- Medical Supportive Care

The mainstay of managing patients with severe COVID-19 disease who have cardiac involvement is supportive care. There is currently no evidence to direct the management of these patients differently than any other inflammatory or "mixed" shock state.

Some general principles include:

- Avoid overaggressive fluid resuscitation given challenges with oxygenation (target CVP 6-8 mm Hg). Higher preload (CVPs 12-15) may also be desirable when significant RV dysfunction and/or high positive end-expiratory pressure (PEEP) states are present. The effective CVP can be calculated by measured CVP – PEEP.
- Target a MAP of 60-65 mm Hg and preferentially start with norepinephrine infusion for hypotension.
- Consider dobutamine in the setting of worsening hypotension with cardiac dysfunction.
- Epinephrine and vasopressin should be considered for refractory hypotension.
- Consideration can be given to using Angiotensin II for refractory vasoplegia.

Mechanical Support/ECMO

There are several factors that must be considered prior to placing a patient with COVID-19 on ECMO support. ECMO is a limited resource and should be reserved for those with the greatest chance of recovery. Therefore, ECMO should not be considered in futility.

- The majority of patients being considered for ECMO with COVID-19 disease will have refractory hypoxemia and respiratory acidosis despite advanced ventilator management.



In these patients, VV ECMO via internal jugular vein access is most appropriate.

- However, in patients with significant cardiomyopathy and cardiogenic shock, a VA ECMO configuration might be necessary.

As discussed above, the use of hemodynamic surrogates and echocardiogram findings can help direct this decision. To this end, VA ECMO has been used to successfully support a patient with COVID-19 who had combined respiratory failure and cardiomyopathy.

- As the majority of patients with circulatory failure also have profound hypoxia, the utility of other cardiac support devices such as intra-aortic balloon pump, TandemHeart or Impella is limited.
- The mainstay of managing patients with severe COVID-19 disease who have cardiac involvement is supportive care.
- There is currently no evidence to direct the management of these patients differently than any other inflammatory or "mixed" shock state.
- Experimental strategies including antiviral, anti-inflammatory, convalescent sera are being considered as part of research protocols or compassionate use for COVID-19 infection with or without cardiac involvement.

What are the key considerations for managing AFib during COVID-19? ⁽³⁾

While there is no evidence of a direct association between COVID-19 and new-onset atrial fibrillation (AFib), serious viral illness is known to precipitate arrhythmia; particular caution should be taken to manage drug-drug interactions between commonly used COVID therapies and antiarrhythmics and anticoagulants.

Does treatment for COVID-19 affect the use of antiarrhythmic medications for AFib?

Drugs like chloroquine, hydroxychloroquine, azithromycin, lopinavir and ritonavir used in the management of COVID-19 can prolong the QT interval. The effect of remdesivir on the QT interval is unknown. AFib patients on antiarrhythmic agents like dofetilide, sotalol, amiodarone and dronedarone need careful monitoring of the QT interval. When there is significant QT prolongation and COVID treatment is warranted, stopping antiarrhythmic medication is reasonable if clinical circumstances allow. Lopinavir-ritonavir combination increases serum amiodarone (U.S. Food and Drug Administration labeling recommends caution and monitoring of serum amiodarone levels), digoxin and flecainide levels. Similarly, chloroquine and hydroxychloroquine can increase serum amiodarone, digoxin and flecainide levels to a lesser extent. Sotalol and dofetilide may need dosing adjustments in COVID-19 patients with acute kidney injury.

Does treatment for COVID-19 affect anticoagulation for AFib?

Lopinavir-ritonavir combination (combined P-glycoprotein/strong CYP3A4 inhibitor) can potentially reduce warfarin levels and increase apixaban, rivaroxaban and edoxaban levels. FDA labelling suggests reducing apixaban dose to 2.5 mg twice daily if used concomitantly with lopinavir-ritonavir combination. Consider switching to alternate agents (preferably heparin or enoxaparin). Chloroquine and hydroxychloroquine can increase serum apixaban, dabigatran, rivaroxaban and edoxaban levels. Close clinical monitoring is required. Apixaban, dabigatran, edoxaban and rivaroxaban may need dosing adjustment in COVID-19 patients with acute kidney injury.

How do you treat AFib in COVID-19 positive patients?

Where possible, a rate control strategy is preferable, especially in critically ill patients who can tolerate these medications. When anticoagulation is indicated, use of heparin or enoxaparin is preferable in patients where chloroquine, hydroxychloroquine, lopinavir/ritonavir use is anticipated. Antiarrhythmic drugs should be used with caution due to the risk of QT prolongation and drug-drug interactions with the above-mentioned agents.



What are thrombosis risk and management considerations in COVID-19? ⁽⁴⁾

Despite the limited published evidence, most experts agree that the signal for increased thrombotic risk is sufficient to recommend pharmacologic venous thromboembolism (VTE) prophylaxis in all hospitalized COVID-19 patients as long as there is no contraindication.

When clinically appropriate, a single daily low-molecular weight heparin may help minimize staff exposure risk and conserve personal protective equipment (PPE).

The coagulopathy found in severe COVID-19 appears to be associated with normal or increased fibrinogen levels, unlike disseminated intravascular coagulopathy (DIC), and thus does not present a clear increased risk for bleeding.

What is the link between hypertension and COVID-19? ⁽⁵⁾

Although a causal relationship has not been established, early epidemiological evidence suggests a correlation between hypertension and COVID-19 susceptibility and severity

- Initial reports from "hot spots" like Wuhan, New York City, and the Lombardy region of Italy found high rates of hypertension among hospitalized COVID-19 patients.
- In a recent report, 56% of hospitalized COVID-19 patients in a large New York health care system presented with a diagnosis of hypertension.
- In case series, patients with hypertension and COVID-19 infection have higher rates of morbidity and mortality.
- Many hospitalized COVID-19 patients are older with multiple comorbidities; there is no clear evidence of a causal link between hypertension and COVID-19-related morbidity and mortality.
- Hypertension remains the greatest modifiable risk factor for atherosclerotic cardiovascular disease.

- Clinicians should continue to follow the 2017 ACC/AHA blood pressure management guidelines to reduce long-term cardiovascular risk associated with hypertension.

What is the role of RAAS inhibitors in COVID-19? ⁽⁶⁾

Currently there are no experimental or clinical data demonstrating beneficial or adverse outcomes with background use of ACE inhibitors, ARBs or other RAAS antagonists in COVID-19 or among COVID-19 patients with a history of cardiovascular disease treated with such agents.

- The HFSA, ACC, and AHA recommend continuation of RAAS antagonists for those patients who are currently prescribed such agents for indications for which these agents are known to be beneficial, such as heart failure, hypertension, or ischemic heart disease.
- In the event patients with cardiovascular disease are diagnosed with COVID-19, individualized treatment decisions should be made according to each patient's hemodynamic status and clinical presentation.
- Therefore, be advised not to add or remove any RAAS-related treatments, beyond actions based on standard clinical practice.

What is the role of BNP measurement in COVID-19? ⁽⁷⁾

Natriuretic peptides are biomarkers of myocardial stress are frequently elevated among patients with severe respiratory illnesses, typically in the absence of elevated filling pressures or clinical heart failure.

- Much like troponin, elevation of BNP or NT-proBNP is associated with an unfavorable course among patients with ARDS.



What is the role of troponin measurement in COVID-19? ⁽⁸⁾

Troponin is commonly elevated in patients COVID-19 and does necessarily indicate myocardial infarction (MI) or other cardiac sequelae; routine monitoring of troponin is indicated upon clinical suspicion of MI or cardiac dysfunction.

- Rise and/or fall of troponin – indicating myocardial injury – is common among patients with acute respiratory infections and correlates with disease severity.
- Abnormal troponin values are common among those with COVID-19 infection particularly when a high sensitivity cardiac troponin (hs-cTn) assay is used.
- Detectable hs-cTn is observed in most patients with COVID-19 and significantly elevated in more than half of the patients who died.
- The mechanisms underlying myocardial injury in those with COVID-19 infection are not fully understood. However in keeping with other severe respiratory illnesses, direct ("non-coronary") myocardial damage is almost certainly the most common cause.
- Given the presence of abundant distribution of ACE2 – the binding site for the SARS-CoV-2 in cardiomyocytes – some have postulated that myocarditis might be a common cause.
- Support for this comes from reports of COVID-19-related acute left ventricular failure. Other possibilities include acute MI – either Type 1 MI based on plaque rupture triggered by the infection or Type 2 MI based on supply-demand inequity.
- Importantly, a rise and/or fall of troponin is insufficient to secure the diagnosis of acute MI; rather, it should be based on clinical judgment, symptoms and signs, and ECG changes.
- Given the frequency and nonspecific nature of abnormal troponin results among patients with COVID-19 infection, clinicians are advised to only measure troponin if the diagnosis of acute MI is being considered on clinical grounds.
- In addition, an abnormal troponin should not be considered evidence for an acute MI without corroborating evidence.

What are some considerations for echocardiography in COVID-19? ⁽⁹⁾

Echocardiography is an essential imaging modality to assess cardiac complications of viral infection as well as manage COVID+ patients with underlying cardiovascular disease. However, in the context of infectious disease, modifications of standard procedure may be warranted.

Point-of-care ultrasound (POCUS) may be advisable for COVID positive patients because it allows in-room patient evaluation while minimizing staff exposure.

How to image? Here is a suggested abbreviated ECHO protocol for COVID -19 patients ⁽¹⁰⁾

Subcostal Long Axis

-2D Image

- Color Doppler of Mitral Valve and Tricuspid valve
- CW Doppler of Tricuspid valve if possible

Subcostal Short Axis

-IVC Diameter

-2D Short Axis of LV at Papillary level (for LV function)

- 2D Subcostal short axis
- Color Doppler of Tricuspid valve
- CW Doppler of Tricuspid valve if possible

Apical 4 Chamber

-2D Image

2D of LV (zoomed or not, depending on image quality) with focus on EF.

- 3D Heart Model if images are adequate.
- Color Doppler of Mitral valve and Tricuspid valve
- CW Doppler of Tricuspid valve.

Apical 5 Chamber

-2D Image

- Color Doppler of Aortic valve
- CW Doppler of Aortic valve.



Apical 2 Chamber

- 2D Image
- 2D of LV (zoomed or not, depending on image quality) with focus on EF.
- Color Doppler of Mitral valve only if suspected severe MR.

Apical 3 Chamber

- 2D Images
- Color Doppler and CW Doppler of Aortic valve only if suspected severe AS or AI.

No Images from the PLAX (parasternal long axis) or PSAX (parasternal short axis).

TEEs carry a heightened risk of spread of the SARS-CoV-2 since they may provoke aerosolization of a large amount of virus due to coughing or gagging that may result during the examination.

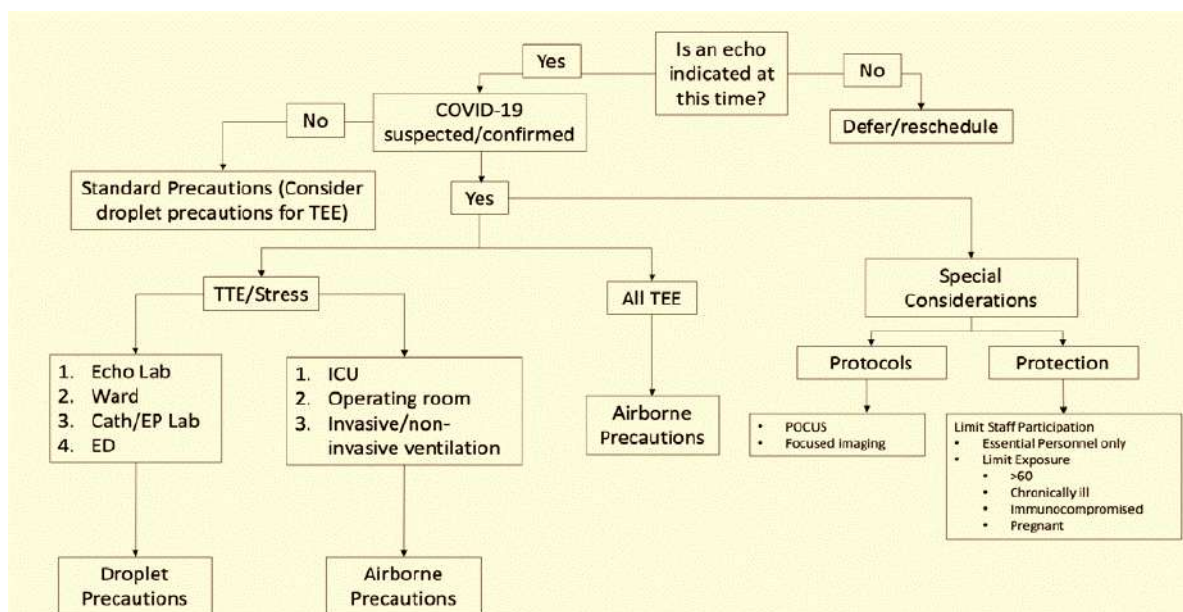
TEEs therefore deserve special consideration in determining when and whether they should be performed, and under what precautions (described below). A cautious consideration of the benefit of a TEE examination should be weighed against the risk of exposure of healthcare personnel to aerosolization in a patient with suspected or confirmed COVID-19 and the use of PPE. TEEs should be postponed or canceled if an alternative imaging modality (e.g. off axis TTE views, ultrasound enhancing agent with TTE) can provide the necessary information.

Protection

Personnel Imaging should be performed according to local standards for the prevention of virus spread. The types of PPE can be divided into levels or categories (see Table below).

- Standard care involves handwashing or hand sanitization and use of gloves. The use of a surgical face mask in this setting may also be considered.
- Droplet precautions include gown, gloves, headcover, facemask and eye shield.
- Airborne precautions add special masks (e.g. N-95 or N-99 respirator masks, or powered air purifying respirator - PAPR systems), and shoe covers. The local application of each component of PPE can vary according to level or type of risk for TTEs and stress echo exams, but airborne precautions are required during a TEE for suspected and confirmed cases, due to the increased risk for aerosolization. A surgical face mask for patients is recommended for those who are symptomatic, undergoing surface echo examination provided institutional resources allow this strategy for source control.

Suggested algorithm for determining indication and level of protection





Pharmacy & Therapeutics Clinical Consensus Group
COVID-19 Corticosteroid Guidance
June 18, 2020

Corticosteroid Treatment

- No FDA approved indication for corticosteroid use in COVID-19
- Corticosteroids are associated with adverse effects including hyperglycemia and neurologic toxicity
- Limited data available on the use of corticosteroids in COVID-19 with mixed results
- Recent publications evaluating methylprednisolone and/or dexamethasone for patients with ARDs and/or COVID-19 suggest possible benefit although evidence is inconclusive
- Banner recommendations are based on available literature, current utilization patterns within Banner, side effect profile, disease severity and expert consensus
- The following guidance is offered for clinicians wanting to use corticosteroids for COVID-19 patients and is subject to change as more information becomes available

Guidance for Use	Hospital Setting	Corticosteroid Recommendation		
		Medication	Dosing	Duration*
COVID PCR positive + SpO2 < 94% on room air requiring initiation of supplemental oxygen (≥4L) or mechanical ventilation + 48 hours or less from hospital admission Monitoring: Blood Glucose Delirium	Non-Critical Care	Dexamethasone	6 mg PO daily	5 days
		Methylprednisolone (0.5-1 mg/kg/day)	≤ 80 kg: 40 mg IV Push daily 81-120 kg: 40 mg IV Push Q12H > 120 kg: 40 mg IV Push Q8H	5 days
	Critical Care	Dexamethasone	10 mg IV Push or PO daily	7 days
		Methylprednisolone (0.5-1 mg/kg/day)	≤ 80 kg: 40 mg IV Push daily 81-120 kg: 40 mg IV Push Q12H > 120 kg: 40 mg IV Push Q8H	7 days
	Critical Care on Mechanical Ventilation	Dexamethasone	10 mg IV Push or PO daily	10 days
		Methylprednisolone (0.5-1 mg/kg/day)	≤ 80 kg: 40 mg IV Push daily 81-120 kg: 40 mg IV Push Q12H > 120 kg: 40 mg IV Push Q8H	10 days
Additional Information				
<ul style="list-style-type: none">• CRP monitoring is not recommended• If patient demonstrates continued inflammatory state after defined treatment period, consider reducing dose and tapering over 7-10 days• Patients with ARDS due to influenza have demonstrated increased rate of secondary infections and mortality, recommend excluding them from this treatment• Higher doses than listed not recommended in COVID19; Adverse effects of steroids are more likely to occur with higher doses and longer durations of therapy including secondary infection, hyperglycemia, psychosis, avascular necrosis, peptic ulcer exacerbation, and pancreatitis; if higher doses used, reasons should be documented (i.e. adrenal insufficiency)				

COVID-19 CORTICOSTEROID GUIDANCE | 06.18.20 @1800



Updates

Medication	Clinical Evidence	Dose and Safety Considerations	Comments
<p>Corticosteroids</p> <p><i>Updated 6/18/20</i></p> <p>Potent anti-inflammatory and antifibrotic properties; low doses of corticosteroids may prevent an extended cytokine response and may accelerate resolution of pulmonary and systemic inflammation in pneumonia.^{3,9}</p> <p>Evidence suggests that cytokine storm, a hyperinflammatory state resembling secondary hemophagocytic lymphohistiocytosis (HLH), is a contributing factor in COVID-19-associated mortality.^{8,18} Immunosuppression from corticosteroids has been proposed as a treatment option for such hyperinflammation.¹⁸</p> <p>May improve dysregulated immune response caused by sepsis (possible complication of infection with COVID-19) and increase BP when low.^{4,11}</p>	<p>Observational studies: Evidence suggests that corticosteroids in patients with SARS and MERS showed no survival benefit and possible harm (e.g., delayed viral clearance, avascular necrosis, psychosis, diabetes).² Systemic corticosteroid therapy has been studied in several randomized controlled studies for the treatment of acute respiratory distress syndrome (ARDS); overall evidence is low to moderate in quality and most studies were performed prior to the pre-lung protection strategy era.^{5,9,14}</p> <p>Conflicting results reported for use of corticosteroids (e.g., hydrocortisone) for treatment of sepsis.⁴</p> <p>A single center, retrospective, propensity matched study from China of 244 critically ill patients with COVID-19 analyzed outcomes in those who received a corticosteroid (products were not specified) compared to those who did not. 151/244 patients received corticosteroids with a median of 200 mg of hydrocortisone equivalents per day. Median duration of corticosteroid treatment was 8 days. Multivariate analysis adjusting for major mortality-associated variables and propensity score did not find an association between corticosteroid use and 28 day mortality. 31 patients were matched to controls who did not receive corticosteroids. 28 day mortality in those who received corticosteroids was higher than those who did not receive corticosteroids, though this difference was not statistically significant (39% vs. 16%, $p=0.09$).²⁹</p> <p>WHO and expert consensus statement from Chinese Thoracic Society: Basic principles should be followed when using corticosteroids: (1) benefits and risks should be carefully weighed before using corticosteroids; (2) corticosteroids should be used prudently in critically ill patients with 2019-nCoV pneumonia; (3) for patients with hypoxemia due to underlying diseases or who regularly use corticosteroids for chronic diseases, further use of corticosteroids should be cautious and (4) dosage should be low to moderate ($\leq 0.5-1$ mg/kg daily of methylprednisolone or equivalent) and duration should be short (≤ 7 days).¹⁷ Chinese health authority states that corticosteroids can be used in patients with COVID-19 who experience progressive deterioration for a short period of time (3-5 days) and at dosages not exceeding methylprednisolone 1-2 mg/kg daily or equivalent.¹⁰</p>	<p>Regimens used in China were typically methylprednisolone 40-80 mg IV daily for a course of 3-6 days.⁸ Some experts suggest that equivalent dosages of dexamethasone (i.e., 7-15 mg daily, typically 10 mg daily) may have an advantage of producing less fluid retention, since dexamethasone has less mineralocorticoid activity.⁸ This dosage of dexamethasone is consistent with those used in the DEXAARDS trial.^{8,17}</p> <p>Higher dosages have been suggested for cytokine storm. (e.g., IV methylprednisolone 60-125 mg every 6 hours for up to 3 days) followed by tapering of the dose when inflammatory markers (e.g., C-reactive protein levels) begin to decrease.⁸</p>	<p>Data on the use of corticosteroids in COVID-19 are limited and demonstrate mixed results.^{3,5,7,24-29} The benefits and risks of corticosteroid therapy should be carefully weighed in patients with COVID-19.^{1,7}</p> <p>WHO, CDC, and NIH generally recommend against the routine use of corticosteroids for the treatment of COVID-19 unless indicated for another reason (e.g., asthma or COPD exacerbation, refractory septic shock).^{1,2,3,8,9,24}</p> <p>The Surviving Sepsis Campaign COVID-19 subcommittee recommends against the routine use of systemic corticosteroids in mechanically ventilated adults with COVID-19 and respiratory failure without ARDS.¹² However, these experts generally support a weak recommendation to use low-dose, short-duration systemic corticosteroids in the sickest patients with COVID-19 and ARDS.¹²</p> <p>Cytokine storm: There is no well-established or evidence-based treatment for cytokine storm in patients with COVID-19.⁸ However, some experts suggest that use of more potent immunosuppression with corticosteroids may be beneficial in such patients. See dosing section for doses recommended.</p>



<p>Methylprednisolone</p> <p><i>Updated 6/10/20</i></p> <p>Potent anti-inflammatory and antifibrotic properties; low doses of corticosteroids may prevent an extended cytokine response and may accelerate resolution of pulmonary and systemic inflammation in pneumonia ^{3,9}</p>	<p>Retrospective, observational, single-center study: In 201 patients with confirmed COVID-19 pneumonia who developed ARDS, methylprednisolone appeared to reduce the risk of death.⁶ Among patients with ARDS, of those who received methylprednisolone treatment, 23 of 50 (46%) patients died, while of those who did not receive methylprednisolone, 21 of 34 (61.8%) died.</p> <p>A pre-post, quasi-experimental, observational, multicenter study in Michigan analyzed the impact of a new protocol using a short course of methylprednisolone in 213 pts with COVID-19. Adult patients with radiographic evidence of bilateral pulmonary infiltrates who required oxygen by nasal cannula, high-flow nasal cannula, or mechanical ventilation were included. Those treated prior to the corticosteroid protocol were compared to those treated after the implementation of the protocol. The corticosteroid protocol consisted of methylprednisolone 0.5 - 1 mg/kg/day IV divided in two doses for 3 days. The post-protocol arm had a lower rate of composite endpoint of escalation to ICU, progression to respiratory failure requiring mechanical ventilation after hospital admission, or in hospital all-cause mortality than the pre-protocol arm (34.9% vs. 54.3%, p=0.005). The post-protocol arm also had a shorter length of stay and lower rates of ARDS. Interesting, a majority of patients in both arms received corticosteroids (68.2% vs. 56.8%, p=0.094), but patients were initiated earlier in the post-protocol arm (2 vs. 5 days after admission, p<0.001).²⁵</p> <p>A retrospective cohort study looked at methylprednisolone use in 46 patients with severe COVID-19 pneumonia in China. 26 patients received intravenous methylprednisolone 1-2 mg/kg/day for 5-7 days. 5.4% of patients died. They observed several positive associations in those who received methylpred, including faster improvement in SPO2, shorter time on supplemental O2 (median 8 days vs. 14 days, p<0.001), and lower rates of mechanical ventilation (11.5% vs. 35%, p=0.05). Median LOS and median ICU LOS were both significantly shorter for patients who received methylpred (14 vs. 22 days, p<0.001 and 8 vs 15 days, p<0.001, respectively.²⁶</p> <p>A single-center case series from China reported outcomes in 15 severe and critical patients who received a single dose of methylprednisolone 40-500 mg. The observed that only 1 of the 15 pts required mechanical ventilation no deaths occurred. They also did not report any adverse effects.²⁷</p> <p>A single-center retrospective cohort study from China compared those who received methylprednisolone to those that did not. Methylpred dose administered was 40 mg once or twice daily was administered to 11 patients within 24 hours of admission and these patients were compared to the other 20 patients who did not receive methylpred (total n=31 patients). The authors noted that methylpred pts had a higher Tmax and had more symptoms of COVID upon admission. These patients also had bilateral involvement on chest CT more frequently than pts who did not receive methylpred. No statistically significant differences in viral clearance or clinical outcomes were noted between groups.²⁸</p>	<p>Dosage used in this retrospective study not provided.⁶ Based on expert consensus statement from Chinese Thoracic Society, dosage of methylprednisolone should be low to moderate (i.e., ≤ 0.5 to 1 mg/kg daily or equivalent).⁷ Regimens used in China were typically methylprednisolone 40-80 mg IV daily for a course of 3-6 days.</p>	
---	--	---	--



Updates

Dexamethasone <i>Updated 6/18/20</i> Potent anti-inflammatory and weak mineralocorticoid effects compared to other steroids. Long duration of action provides convenient dosing regimen.	Investigator-initiated, multicenter, RCT in 17 ICUs across Spain from March 2013-December 2018. Intubated and mechanically ventilated adults with early, moderate-to-severe, ARDS were included. Intervention group saw decreased ventilator days (12.3 vs. 7.5), ICU mortality, and all-cause mortality at day 60. In the multi-center adaptive RCT, Randomized Evaluation of COVID-19 Therapy (RECOVERY) trial, an interim analysis of 2104 patients randomized to receive dexamethasone were compared to 4321 patients randomized to usual care. Dexamethasone reduced deaths by one-third in ventilated patients and one fifth in patients on oxygen only, correlating with an NNT of 8 ventilated patients and 25 patients on supplemental oxygen. Full details of the trial are still pending peer-review and publication.	Dexamethasone 20 mg daily for five days, then 10 mg daily for days six through ten. Continued dexamethasone for a total of ten days, unless extubated prior to day ten. Then, dose was given prior to extubation and then stopped. Dexamethasone 6mg one daily (IV or PO) for 10 days	Potency of steroid and therefore possibility for steroid induced adverse effects are possible. Starting dose in this study dexamethasone 20 mg IV daily = methylpred 100 mg = prednisone 130 mg = hydrocortisone 500 mg
---	---	--	---

Pharmacy and Therapeutics Clinical Consensus Group COVID-19 Antiviral Medication Treatment Guidelines June 18, 2020

Supportive Care is first line therapy for treatment of COVID19

Antiviral Medication Treatment

- ☐ No FDA approved antivirals for COVID-19
- ☐ Several antivirals and immunomodulators are being investigated
- ☐ Information on safety and efficacy for COVID-19 is evolving with new literature released regularly
- ☐ Banner recommendations based on current literature, drug availability and disease severity
 - o Recommendation to limit use of antiviral therapy to clinical trials where feasible

Remdesivir Treatment Guidelines

- ☐ The U.S. Food and Drug Administration (FDA) has issued an Emergency Use Authorization (EUA) to permit the emergency use of the unapproved product remdesivir for treatment of COVID-19. See EUA fact sheet for providers at <https://www.fda.gov/media/137566/download>
- ☐ Distribution of remdesivir for EUA is managed by HHS and the State Health Departments with limited availability
- ☐ Criteria developed to allocate and prioritize based on limited availability and allocation process outlined below
- ☐ Criteria in alignment with EUA and State of AZ released **Remdesivir Allocation Guidance Approved by State Disaster Medical Advisory Committee 6/12/20.**

Emergency Authorization Criteria for Use	Prioritization	Respiratory Criteria	Recommendation
Inclusion Criteria: COVID PCR positive + Respiratory Criteria Exclusion Criteria: <ul style="list-style-type: none"> <input type="checkbox"/> ALT \geq 5 times the upper limit of normal (ALT \geq 300) <input type="checkbox"/> Patients with an eGFR < 30 ml/min including patients on HD or hemofiltration Requirements for Use: <ul style="list-style-type: none"> <input type="checkbox"/> Provider should discuss remdesivir and provide fact sheet to patients/caregivers prior to administering med. (Available in Krames) <input type="checkbox"/> Report all serious adverse events to FDA 	Highest Priority	Respiratory Support* (3 of 4 characteristics) SpO ₂ < 94% on room air Initiation of supplemental oxygen Respiratory Rate >30 Lung infiltrates on imaging	<input type="checkbox"/> 200 mg IV Day #1, then 100 mg IV daily days 2-5 (5-day course)
	Second Highest Priority	Invasive Mechanical Ventilation** or Patients on ECMO (Mechanical Ventilation and/or ECMO for 5 days or less)	<input type="checkbox"/> 200 mg IV Day #1, then 100 mg IV daily days 2-10 (10-day course)



Hydroxychloroquine Guidelines

- ☐ The US Food and Drug Administration has **revoked** its emergency use authorization for the drugs hydroxychloroquine and chloroquine for the treatment of Covid-19
- ☐ Use of hydroxychloroquine for COVID-19 should be avoided unless given in a clinical trial.
- ☐ If used outside of a clinical trial, the provider **must** review with patient/family the associated risks including increased incidence of adverse cardiac events and increased mortality.
- ☐ If provider determines benefit clearly outweighs risk,
 - Can consider Hydroxychloroquine (HCQ) 400 mg PO BID x 2 doses, then 200 mg PO BID x 4 days
 - Use with caution in patients with cardiac history
 - Avoid use in patients on other QT prolonging meds including azithromycin and levofloxacin
 - Obtain baseline ECG
 - Daily ECG or continuous cardiac monitoring with QTc capture every shift during course of therapy
 - QT monitoring as outlined below

QT Monitoring for Hydroxychloroquine	
Initiation	<ul style="list-style-type: none"><input type="checkbox"/> Discontinue and avoid all other non-critical QT prolonging agents<input type="checkbox"/> Complete list of medications that can prolong QT available at crediblemeds.org<input type="checkbox"/> Assess baseline QTc, renal function, hepatic function, serum potassium, calcium and magnesium;<input type="checkbox"/> Replace electrolytes (target potassium ≥ 4 and magnesium ≥ 2)<input type="checkbox"/> Contact provider if baseline QTc > 500 msec (550 msec if baseline QRS width is >120 msec)
Monitoring	<ul style="list-style-type: none"><input type="checkbox"/> Baseline 12-lead ECG prior to initiation of therapy<input type="checkbox"/> Monitor QTc via cardiac monitor in order to minimize staff exposure and PPE utilization<input type="checkbox"/> For patients with prolonged QTc or borderline via monitor, a 12 lead ECG could be considered<input type="checkbox"/> Assess QTc 2-3 hours after 1st dose and then every 24 hours during course of therapy
QT Prolongation	<ul style="list-style-type: none"><input type="checkbox"/> Assess potassium, calcium and magnesium; replace electrolytes and magnesium as needed<input type="checkbox"/> Review medications and discontinue all other non-critical QT prolonging agents<input type="checkbox"/> If QTc increases by > 60 msec from baseline or absolute QTc becomes > 550-570 (If baseline QRS is > 120 msec, then add 50 msec to these recommendations for discontinuation)<ul style="list-style-type: none">○ Re-evaluate the risk/benefit of therapy○ Consider discontinuing azithromycin (if receiving)○ Consider discontinuation of HCQ if on alone and monitor QTc until returns to baseline<input type="checkbox"/> If QTc remains increased despite discontinuation of azithromycin, consider discontinuing therapy<input type="checkbox"/> If therapy is stopped due to QTc prolongation, re-challenging a patient may be considered if benefit is thought to be greater than the risk.<ul style="list-style-type: none">○ Restart hydroxychloroquine 200 mg BID once QTc returns to baseline and monitor with QTc with each dose. (Note: long elimination half-life of hydroxychloroquine similar to amiodarone)
Brady and long QT	<ul style="list-style-type: none"><input type="checkbox"/> See COVID-19 toolkit for treatment recommendations.



COVID-19 Related Medication Treatment Summary

Adapted from Assessment of Evidence for COVID-19-Related Treatments. Bethesda, MD: American Society of Health-System Pharmacists, Inc.

Updates

Medication	Class	Comments	Banner Recommendation
Antivirals			
Baloxavir	Antiviral	No data to date support use in the treatment of COVID-19	Not recommended
Chloroquine Phosphate	Antimalarial	Active in vitro against SARS-CoV1 and SARS-CoV-2. Limited clinical data published. Multiple clinical trials initiated. Chloroquine is suggested a possible option in some international guidelines for treatment of COVID-19 but currently not recommended as first line therapy at BH given drug availability and published data. One trial in Brazil halted because of safety concerns with higher dosing regimens (600 mg bid).	Not recommended
Favipiravir	Antiviral	Benefit is uncertain given mixed result in trials. Clinical trials ongoing. Investigational agent not available in the US.	Not recommended/ Not available in US
Darunavir/Cobicistat	HIV Protease Inhibitor	HIV-1 protease inhibitor currently being evaluated in a clinical trial (NCT04252274). There is one in vitro study that shows no activity against SARS-CoV-2 at clinically relevant doses.	Not recommended
Hydroxychloroquine	Antimalarial	Active in vitro against SARS-CoV, MERS-CoV2, and SARS-CoV-2. Small studies have been done, most without a comparator group, small number of patients, and lower quality of evidence. Thus, it is difficult to infer benefit. There have been a couple studies in patients with mild disease that have shown positive results (viral clearance, possible efficacy cough relief, temperature normalization, and CT improvement in patients with mild disease). Four studies found no difference between groups in regards to negative conversion rate, ICU transfers, death, advancing to ARDS and LOS. Lastly, there has been concerns raised with HCQ use in hospitalized pts and oxygen requirements. Those pts did have higher baseline requirements. Dosing between studies has not been consistent. Based on study results, there is no clear evidence that this therapy provides benefit. It may benefit pts with more mild disease, but it is unknown at this time which pt population it is best suited for and what dose is optimal. This medication has the best availability within Banner. It could be considered on a risk vs. benefit assessment on a case by case basis. QTc monitoring is recommended if used as QT prolongation has been seen in studies and within our health system.	Not recommended A risk vs. benefit assessment should be done prior to initiation if therapy is desired. If therapy is ordered, recommended dose is HCQ 400 mg bid X 2 doses, then 200 mg bid X 4 days. QTc monitoring should be done. It is not recommended for use with azithromycin. See P & T Guidelines
Ivermectin	Antiparasitic	Only been shown in one in study to inhibit viral replication in vitro. No clinical trials currently or use in COVID-19 patients.	Not recommended
Lopinavir/Ritonavir (LPV/RTV; Kaletra®)	HIV Protease Inhibitor	Given the lack of therapeutic benefit seen in studies, use is not recommended at this time.	Not recommended
Neuraminidase inhibitors (e.g., oseltamivir)	Antiviral	No data to date to support use in the treatment of COVID-19.	Not recommended
Nitazoxanide	Antiprotozoal	Currently no known published clinical data regarding efficacy or safety in the treatment of COVID-19.	Not recommended
Remdesivir	Antivirals, Miscellaneous	ACTT Trial showing faster time to recovery in patients receiving remdesivir than placebo but no overall difference in mortality. In addition, there has been additional data published showing no difference in 10 days of therapy versus 5 days in severe non intubated patients. Emergency use authorization issued. Currently, Banner Health has received a limited supply of remdesivir for use. Please see P&T criteria for use. Compassionate use is still available for pediatric and pregnant patients.	See P&T guidelines for criteria for use
Umifenovir (Arbidol®)	Antiviral	Currently not available in the United States. Studies show mix results when compared to lopinavir/ritonavir. No data to support its use in COVID-19.	Not recommended/ Not available in US

COVID-19 ANTIVIRAL GUIDELINES | 06.18.20 @1800



References

1. ACC, SCAI, ACEP Release Consensus Statement on Management of AMI Patients During COVID-19 <https://www.acc.org/latest-in-cardiology/articles/2020/04/29/12/42/key-questions-faq-on-covid-19-coronavirus-disease-2019-and-cardiovascular-disease#eleven>
2. Management of the Hospitalized COVID-19 Patient with Acute Cardiomyopathy or Heart Failure <https://www.acc.org/latest-in-cardiology/articles/2020/04/29/12/42/key-questions-faq-on-covid-19-coronavirus-disease-2019-and-cardiovascular-disease#seven>
3. Bharath Rajagopalan, MD, FACC; Rachel Lampert, MD, FACC; Dhanunjaya Lakkireddy, MD, FACC. Managing AFIB during COVID-19 [https://www. acc.org/latest-in-cardiology/articles/2020/04/29/12/42/key-questions-faq-on-covid-19-coronavirus-disease-2019-and-cardiovascular-disease#sixteen](https://www.acc.org/latest-in-cardiology/articles/2020/04/29/12/42/key-questions-faq-on-covid-19-coronavirus-disease-2019-and-cardiovascular-disease#sixteen)
4. Thrombosis and COVID-19: FAQs for Current Practice. <https://www.acc.org/latest-in-cardiology/articles/2020/04/29/12/42/key-questions-faq-on-covid-19-coronavirus-disease-2019-and-cardiovascular-disease#ten>
5. Eugene Yang, MD, FACC; Anandita Agarwala, MD; Lisa Martin, MD, FACC; Arjun Kanwal, MD; Eileen Handberg, PhD, FACC <https://www.acc.org/latest-in-cardiology/articles/2020/04/29/12/42/key-questions-faq-on-covid-19-coronavirus-disease-2019-and-cardiovascular-disease#seven>
6. HFSA/ACC/AHA Statement Addresses Concerns Re: Using RAAS Antagonists in COVID-19 [https://www. acc.org/latest-in-cardiology/articles/2020/03/17/08/59/hfsa-acc-aha-statement-addresses-concerns-re-using-raas-antagonists-in-covid-19](https://www.acc.org/latest-in-cardiology/articles/2020/03/17/08/59/hfsa-acc-aha-statement-addresses-concerns-re-using-raas-antagonists-in-covid-19)
7. Troponin and BNP use in COVID-19. [https://www. acc.org/latest-in-cardiology/articles/2020/04/29/12/42/key-questions-faq-on-covid-19-coronavirus-disease-2019-and-cardiovascular-disease#one](https://www.acc.org/latest-in-cardiology/articles/2020/04/29/12/42/key-questions-faq-on-covid-19-coronavirus-disease-2019-and-cardiovascular-disease#one)
8. Troponin and BNP use in COVID-19. [https://www. acc.org/latest-in-cardiology/articles/2020/04/29/12/42/key-questions-faq-on-covid-19-coronavirus-disease-2019-and-cardiovascular-disease#one](https://www.acc.org/latest-in-cardiology/articles/2020/04/29/12/42/key-questions-faq-on-covid-19-coronavirus-disease-2019-and-cardiovascular-disease#one)
9. Source: ASE Statement on Protection of Patients and Echocardiography Service Providers During the 2019 Novel Coronavirus Outbreak [https://www. acc.org/latest-in-cardiology/articles/2020/04/06/18/10/acc-endorses-ase-statement-on-echocardiography-protection-for-patients-providers-during-covid-19](https://www.acc.org/latest-in-cardiology/articles/2020/04/06/18/10/acc-endorses-ase-statement-on-echocardiography-protection-for-patients-providers-during-covid-19)
10. <https://www.asecho.org/covid-19-resources>
11. Pharmacy and Therapeutics Clinical Consensus Group COVID-19 Medication Treatment Guidelines June 18, 2020, Banner Healthcare System, Arizona, USA. (Corticosteroid and antiviral)



Updates

COVID-19 and Acute Coronary Syndromes: Implications and considerations

F. Aaysha Cader

Assistant Professor & Associate Consultant, Department of Cardiology

Ibrahim Cardiac Hospital & Research Institute, Dhaka

E-mail: aaysha.cader@gmail.com

Abstract

Declared a pandemic by the World Health Organization (WHO) in March 2020, the severe acute respiratory syndrome coronavirus 2 (SARS-CoV2) not only causes a viral pneumonia but has major implications for the cardiovascular system, with presentations ranging from myocardial injury to myopericarditis, arrhythmia and acute coronary syndromes (ACS). A significant portion of patients with Coronavirus disease 2019 (COVID-19) have elevated cardiac biomarkers, and may represent an acute myocardial injury with a variety of aetiologies. As such, one needs to differentiate a Type I acute myocardial infarction (AMI) due to plaque rupture versus myocarditis, stress cardiomyopathy, coronary spasm, or Type II AMI due to supply-demand mismatch. Given its robust capacity for human-to-human transmission and potential of being a nosocomial source of infection, COVID-19 has specific implications on healthcare systems and health care professionals, faced with performing essential cardiac procedures in patients with a suspected or confirmed diagnosis of COVID-19. The primary goals in delivering emergency medical care during a pandemic are to ensure the efficient and time-appropriate delivery of emergency services especially in cases such as ST-segment elevation myocardial infarction (STEMI), and in doing so, to also limit the transmission of infection among healthcare workers and other in-hospital patients. The challenges to timely reperfusion strategies ACS, and the decision-making between fibrinolysis and primary percutaneous coronary intervention (PCI) are multifold, particularly in hospitals that may be unusually burdened at the height of the COVID-19 pandemic, where timely door-to-balloon time may not be ensured, or where invasive procedures in a cardiac catheterization laboratory were limited by the absence of provision for negative pressure ventilation. This is particularly applicable to resource-constrained healthcare systems, further compounded by the additional challenges of unavailability of widespread on-site testing for SARS-CoV2. This article provides a brief overview of the pathophysiology and cardiovascular implications of COVID-19 with a particular emphasis on pathways of care pertaining to ACS.

Keywords: COVID 19, Acute Coronary syndromes, CVD, RAS

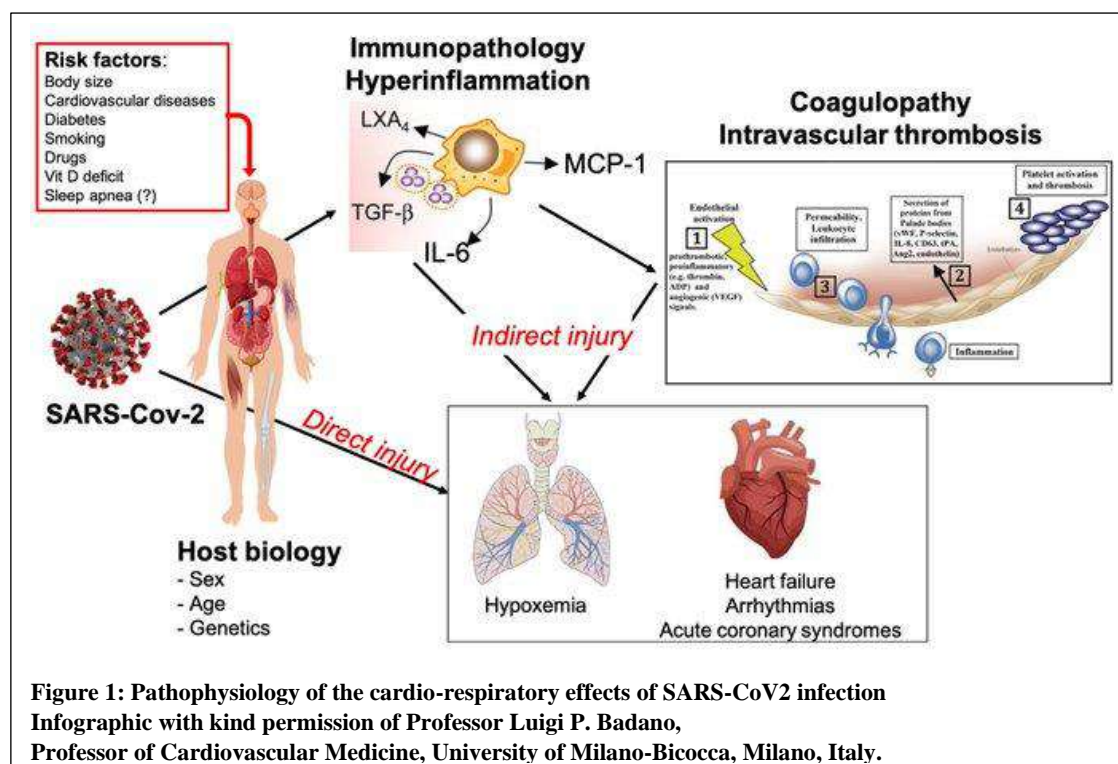
Introduction

The Coronavirus disease 2019 (COVID-19) pandemic, caused by severe acute respiratory syndrome coronavirus-2 (SARS-CoV-2) has 6,057,853 confirmed cases and claimed over 371,166 lives globally, as of 1st June 2020 ⁽¹⁾. Although the clinical picture of COVID-19 has been dominated by the respiratory system, serious cardiovascular consequences, including myocardial injury, myocarditis, acute coronary syndromes (ACS), arrhythmias, heart failure, cardiogenic shock, deep vein thrombosis and pulmonary embolism have been attributed to the disease process caused by SARS-CoV2 ⁽²⁻⁶⁾. Furthermore, it is becoming increasingly evident that patients with pre-existing cardiovascular diseases (CVD), particularly hypertension, coronary artery disease (CAD) and cardiomyopathy appear to have heightened vulnerability to develop COVID-19 and a tendency to more severe disease with worse outcomes ^(2,4,7). Prior data demonstrate that patients with acute respiratory infections were at increased risk for subsequently developing acute myocardial infarction (AMI) after both influenza and non-influenza viral illnesses, including other coronavirus species ⁽⁸⁾, with fatal AMIs being observed in the short term after coronavirus associated SARS ⁽⁹⁾.

The actual prevalence of ACS in the setting of COVID-19 infection is unknown, given the gaps in testing witnessed in numerous countries in the early phases of the pandemic, and particularly in the absence of typical symptoms suggesting COVID-19 infection ⁽²⁾. Especially in this absence of data, ACS during the pandemic deserves special attention not only due to the susceptibility of SARS-CoV2-infected patients, but also owing to the urgency of its diagnosis and rapid institution of prompt revascularization strategies.

The pathophysiology of ACS in COVID-19

The pathobiology of coronavirus infection involves the binding of SARS-CoV-2 to the host receptor angiotensin-converting enzyme 2 (ACE2) which mediates its entry into cells ⁽⁷⁾. ACE2, which is expressed in the lungs, heart and vasculature, is a key member of the renin angiotensin system (RAS) important in the pathophysiology of CVD ^(4, 7, 10, 11). The effects of SARS-CoV2 on the heart and the vasculature possibly result from a combination of direct and indirect injury. Several mechanisms of the interplay in the pathophysiology of the cardio-respiratory effects of SARS-CoV2 infection, including its immunological effects have been proposed, some of which are depicted in Figure 1.



The mechanisms of acute cardiac injury among those infected with SARS-CoV2 are not well established. One possible mechanism could be its affinity to ACE2, which is widely expressed in the heart, and cause direct myocardial injury^(2, 4, 7, 10). Direct infection of endothelial cells or pericytes could lead to macrovascular or microvascular dysfunction and downstream ischemic consequences, as they express ACE-2 receptors to which SARS-CoV2 bind directly^(10, 11).

In case of ACS or AMI, these pathophysiologic effects could be further compounded by the increased coagulability arising from systemic inflammatory response and the ensuing cytokine storm, as evidenced by significantly elevated markers of coagulation, particularly D-dimer levels^(6, 12-15).

Furthermore, immune over-reactivity along with immunometabolism alterations could potentially destabilize atherosclerotic plaques contributing to development of acute coronary events⁽⁴⁾. Underlying this risk are the known predisposing factors related to systemic inflammation: endothelial and smooth muscle cell activation; macrophage activation and tissue factor expression in atheromatous plaque; and platelet activation with further elaboration of inflammatory mediators^(6, 16), all of which, combined with as increased shear stress due to increased coronary blood flow may potentially contribute to plaque rupture, resulting in ACS^(5, 16).

Increased cardiac stress due to an increased cardiometabolic demand associated with the systemic infection coupled with hypoxia caused by acute respiratory illness can impair myocardial oxygen demand-supply relationship leading to acute myocardial injury and a consequent type II MI^(5,6,10).

Myocardial injury versus acute coronary syndromes

Myocardial injury is defined by an elevated cardiac troponin (cTn) value⁽¹⁷⁾, and can be due to myocardial ischemia or non-ischemic myocardial injury, which may arise secondary to myocarditis or may be associated with non-cardiac conditions⁽¹⁷⁾. Acute myocardial injury, manifest by an increased level of biomarkers is not infrequently encountered in COVID19 patients: the overall incidence has been variable. However, initial reports from China revealed that a considerable proportion of patients (12-28%) presented elevated cTn levels^(10, 12, 14, 18-20). Elevated cTn levels have been found to be a significant predictor of poor outcomes and even mortality in multiple studies^(18,19).

Shi et al. reported that 19.7% of the 416 patients studied had cardiac injury defined as high sensitivity troponin I greater than 99th percentile upper reference limit. 57 of the 416 patients died, of whom 10.6% had CAD.



Moreover, in multivariable adjusted models, cardiac injury was significantly and independently associated with mortality⁽¹⁹⁾.

Similarly, Guo et al., reported myocardial injury with elevated troponin T levels in 28% of the 187 patients studied. 35% had underlying CVD. Mortality was significantly higher among those with high cTn levels versus those with normal cTn (59.6% vs 8.9% respectively, $p < 0.001$)⁽¹⁸⁾.

Circulating cTn is a marker of myocardial injury, including but not limited to myocardial infarction (MI) or myocarditis, are commonly elevated in hospitalized patients, and are as likely to be due to non-ischemic causes of myocardial injury or type 2 MI (myocardial oxygen supply-demand imbalance), than as a consequence of ACS⁽²⁰⁾. Furthermore, cTn elevations in patients with COVID-19 infection seem to be lower than in most cases of ACS or acute myocarditis and adequate attention paid to alternate diagnoses such as myocarditis, Takotsubo syndrome, spontaneous coronary dissection, or a type 2 MI⁽²¹⁾. The use of coronary angiography for COVID-19-positive patients with elevation in cTn should be restricted to those in whom type 1 MI is suspected⁽²¹⁾.

Given this range of differential diagnoses of elevated cTn levels in COVID-19 patients, and the distinctly poorer outcomes associated with it, it is imperative that a clear distinction and prompt diagnosis of ACS (i.e. myocardial ischaemia) be made, so as to urgently facilitate appropriate management and revascularization.

Patterns of ACS presentation in COVID-19

This requires recognizing the patterns of presentation of ACS, which is not without challenges, considering the significant overlap in symptoms of ACS with initial presentations of COVID-19, in addition to reports of suggestive ST elevations on electrocardiogram (ECG) eventually revealing non-obstructive coronary arteries on angiography.

The symptom of chest pain or tightness is common in patients with active COVID-19 infection, is usually poorly localized and may be associated with breathlessness due to the underlying pneumonia⁽⁴⁾. Furthermore, an associated profound hypoxaemia together with tachycardia may result in chest pain and accompanying electrocardiographic changes suggestive of myocardial ischaemia⁽⁴⁾.

Where biomarkers are altered, a Type 2 MI may be suggested in such cases. Patients with ACS do, however, experience the more typical symptoms related to ischaemia.

Among 28 COVID-19 patients with STEMI in Lombardy, Italy, 78.6% presented with typical chest pain associated or not associated with dyspnea, while 21.4% had dyspnea without chest pain⁽²²⁾.

Furthermore, cardiac patients may present with out-of-hospital cardiac arrest or cardiogenic shock, arising as a complication of either myocarditis or ACS, necessitating an early, accurate, and rapid evaluation to differentiate its aetiology^(4, 21, 23). Such patients should ideally be transferred and further managed in expert centres which may offer different choices of mechanical circulatory support⁽²¹⁾. An additional differential diagnosis to be borne in mind is acute pulmonary embolism, especially given the increased tendency to hypercoagulability in COVID-19⁽¹⁵⁾.

Early on during the pandemic, cardiologists across the globe noted a drastic reduction in the numbers of ACS presentation, most notably STEMI's presenting to the emergency rooms. Garcia et al, in a preliminary analysis during the early phase of the COVID pandemic showed an estimated 38% reduction in cardiac catheterization laboratory STEMI activations in the United States⁽²⁴⁾, similar to the 40% reduction noticed in Spain⁽²⁵⁾. Tanner, et al, in an elegant paper, detailed potential contributory factors to this reduction, namely altered patient behavior, disrupted care pathways, or altered cardiovascular risk factors pertaining to partial or complete lockdown conditions⁽²⁶⁾. It also detailed the challenges to cardiology services which may arise from decreased or delayed STEMI presentations, especially medium and long-term complications such as heart failure and sudden cardiac death as well as clinical consequences of the un-revascularized cohort⁽²⁶⁾.

The presentations of ACS in COVID-19 have been variable. Before published case series and reports emerged, social media was rife with anecdotes of the so-called "COVID STEMI's", some of which presented with typical ECG changes but yielded no thrombotic occlusions on coronary angiography.

These findings proved to be consistent with published data, emerging not soon after. Stefanini, et al, reported that among 28 STEMI patients with COVID-19 in Lombardy, Italy, STEMI represented the first clinical manifestation of COVID-19 in the majority (85.7%) of cases⁽²²⁾.



Early mortality was 39.3%. All patients underwent urgent coronary angiography and 60.7% had evidence of a culprit lesion requiring revascularization, while 39.3% had no obstructive coronary artery disease.

Bikdeli and colleagues, in a case series of 18 STEMI presentations in New York, reported similar angiographic findings, with 67% of obstructive disease among the 9 patients who underwent angiography⁽²⁷⁾. In that series, 10 out of 18 were identified as noncoronary myocardial injury on the basis of either nonobstructive coronaries on angiography or normal wall motion on echocardiography (if angiography was not done). Furthermore, 4 (22%) of the patients had diffuse ST elevations on ECG, all of whom subsequently had non-obstructive coronaries on angiography. This also underscores the need for paying special attention to the ECG prior to cath lab activation: the absence of reciprocal ST depression, presence of PR segment depression, global ST elevations involving more than a single coronary artery territory are all possible markers indicating that the case may not be one of obstructive coronary artery disease⁽²⁸⁾. The 8 patients (44%) in the New York case series who received a clinical diagnosis of STEMI also had higher median peak troponin and d-dimer levels than those with noncoronary myocardial injury. Overall, in-hospital mortality, was high, at 72%, with 9 of the deaths occurring from among the 10 patients with noncoronary myocardial injury⁽²⁷⁾.

Dominguez-Erquicia and colleagues from Spain reported the case of multivessel 'in situ' coronary thrombosis, in a 64-year-old with no prior risk factors who presented with STEMI, one week after being discharged with COVID-19 pneumonia but no anticoagulation therapy⁽²⁹⁾. A critical thrombotic stenosis of the proximal right coronary artery was stented with a drug eluting stent after thrombus aspiration. A non-occlusive filling defect of the left anterior descending (LAD) artery was confirmed to be thrombus without underlying atherosclerotic plaque on optical coherence tomography of LAD, which was managed medically with dual antiplatelet therapy (DAPT) and heparin.

A case of Takotsubo Syndrome, consistent with classic findings on echocardiography including apical ballooning in a 58-year old diabetic woman was reported by Minhas, et al., possibly the first such case report of stress cardiomyopathy in the setting of COVID-19⁽³⁰⁾. She had presented with a five-day history of productive cough, fever and diarrhea, with diffuse ST segment elevations on ECG and apical ballooning on echocardiography.

She was intubated shortly after presentation due to hypoxic respiratory failure and managed conservatively with angiography deferred, given active COVID-19 infection. Reverse Takotsubo syndrome associated with COVID-19 has also been reported in the literature⁽³¹⁾.

Given the magnitude of such COVID STEMI, and the need for data and shared learning, a COVID ACS Registry by the University of Glasgow on behalf of the University Hospitals of Leicester NHS Trust is currently collecting data via an audit web portal, to enable better understanding of how the COVID-19 virus is affecting those with ACS⁽³²⁾.

Challenges in delivery of ACS care during the pandemic

The primary goals in delivering emergency medical care during a pandemic essentially requires the efficient and time-appropriate delivery of emergency services, especially in cases such as STEMI, and in doing so, to also limit the transmission of infection among healthcare workers and other in-hospital patients.

In addition to patient-related delays in presentation, ensuring timely door-to-balloon times could prove to be challenging given the additional burden of COVID-19 cases, particularly in resource-constrained hospital setting. While this is particularly true for cases of coexistent COVID-19 and ACS, the limitations to reliable on-site rapid testing preclude the possibilities of confidently "ruling out" SARS-CoV2 in persons under investigation (PUI) as well. This is further compounded by the presence of STEMI "mimickers", particularly those with STEMI-like ECG changes and more commonly, the accompanying elevated troponin levels with a consequent need to differentiate them from true ACS^(21, 28).

The importance of point of care ultrasound (POCUS), or targeted screening echocardiography looking for regional wall motion abnormalities cannot be understated, especially in presentations of STEMI, where cath lab activation for primary PCI is of essence^(23, 27). Given that chest CT is frequently used to confirm COVID-19 pneumonia, this might provide possible synergies of and opportunities for cardiac imaging⁽²¹⁾.



As such, it can be considered to integrate the protocol alongside CT coronary angiography, in order to exclude or confirm an ACS, particularly non-ST segment myocardial infarction (NSTEMI) in COVID-19 pneumonia where elevated cTn are common^(21,33,34). Bedside chest radiography can be considered an alternative to chest CT for rapid exclusion of pulmonary infiltrates in patients⁽³³⁾.

Pathways of care in STEMI: Primary PCI versus thrombolysis

In case of STEMI, an early reperfusion may be more important than the mode of reperfusion⁽³⁵⁾. Timely primary PCI relies heavily on systems of care, not just individual operators. System delays in the provision of care of primary PCI during the COVID-19 era arise, even among COVID-19 negative patients, through the steps and time in the emergency room required to establish contact history, symptomatology, chest X ray and other investigations prior to transfer to the cardiac cath lab. Cath lab staff require time to don personal protective equipment (PPE) and may perform their usual roles slower⁽³⁵⁾. Healthcare systems at the height of the pandemic may have stretched out resources, and in such scenarios, a single bolus fibrinolytic in the emergency room may be a feasible alternative⁽³⁵⁾.

Various healthcare systems in different countries across the globe have recommended their approach to treatment of STEMI in the setting of COVID-19 pandemic^(21,23,33,34,36-38). The basis for choosing between primary PCI and fibrinolysis as the default treatment strategy has been primarily based on speed of activating cath lab in order to maintain door-to-wire times, rapid availability of primary PCI operators and presence of catheterization laboratories with negative pressure ventilation^(34,35).

At the inception of the pandemic, Chinese protocols predominantly favoured emergency intravenous thrombolysis within 30 minutes as the first choice for acute STEMI in cases with confirmed COVID-19, in absence of contraindications to fibrinolysis^(33,34). The emphasis was on minimal transmission of infection to healthcare workers (HCWs) with patients being kept in strict isolation until rapid COVID-19 screening tests became available, for those with suspected COVID-19^(33,34).

Nevertheless, in cases of STEMI with low risk of COVID-19, primary PCI remained the preferred strategy with immediate transfer to the cardiac catheterization laboratory^(33,34).

Guidelines by the Cardiological Society of India (CSI) have recommended primary PCI as the preferred strategy for confirmed or suspected COVID-19 patients presenting with STEMI within 12 hours, if performed with the necessary precautions, especially if the patient is haemodynamically unstable. In case of hemodynamically stable patients in whom PCI may not be feasible, thrombolysis has been recommended⁽³⁶⁾.

National Health Service (NHS) guidelines from the United Kingdom also reiterate that primary PCI should be delivered as the default therapy for patients with pain of <12 hours and ST elevation, with specific guidance to manage left bundle branch block (LBBB) in local hospitals unless the patient has ongoing intractable pain⁽³⁷⁾. Thrombolysis, while not preferred for STEMI, may be considered on a case-by-case basis for unstable patients with coronavirus pneumonia who develop a STEMI⁽³⁷⁾.

A joint consensus statement from Society for Cardiovascular Angiography and Interventions (SCAI), American College of Cardiology (ACC), and the American College of Emergency Physicians (ACEP) echoed the general consensus that primary PCI remains the standard of care for STEMI patients at PCI capable hospitals when it can be provided in a timely fashion, with an expert team outfitted with PPE in a dedicated cath lab. A fibrinolysis-based strategy may be entertained at non-PCI capable referral hospitals or in specific situations where primary PCI cannot be executed or is not deemed the best option⁽²³⁾.

As for COVID positive or probable cases presenting with NSTEMI, the overwhelming consensus from different guideline documents is in favour of a conservative strategy of medical management, especially given that the majority of NSTEMI patients do not have ongoing ischaemia and respond well to medical treatment, allowing time to test the patients for COVID-19 infection^(21,23,37). However, they may be taken for urgent coronary angiography and possible PCI in the presence of high-risk clinical features (Global Registry of Acute Coronary Events (GRACE) score >140)20 or hemodynamic instability^(21,34).



Safety of healthcare workers and considerations for cardiac catheterization laboratory

Given its highly contagious nature with proximity dependent spread and viability in aerosols for hours and surfaces for days, SARS-CoV2 poses a significant risk of transmission to HCWs⁽³⁵⁾. The European Association of Percutaneous Cardiovascular Interventions (EAPCI) has stipulated a comprehensive guidance on preparing cath labs and guaranteeing protection to HCWs, in a Position Statement on Invasive Management of ACS during the COVID-19 pandemic⁽²¹⁾. In addition to guidelines on appropriate PPE, they recommend separating HCWs into groups to potentially reduce exposure and therefore limit the operators who may be required to be in quarantine at the same time. A single dedicated “dirty” cath lab should be identified for the treatment of suspected or confirmed COVID-19 cases, with appropriate ventilation systems^(21,33,34). Within the cath lab, a single negative pressure procedure room with essential supplies only is preferable for the care of known COVID-19 positive or probable patients with a scheduled disinfection after the procedure^(21,23,33,34).

Another important issue that arises during STEMI/ACS care particularly pertinent to the cath lab is respiratory compromise requiring intubation. Given that it is an aerosol-generating procedure, the overwhelming consensus is that these patients should be intubated prior to arrival in the CCL if possible. If intubation is required in the CCL, all personnel should have complete PPE and exposures should be minimized to essential team members only, with consideration for Powered Air Purifying Respirator (PAPR) for all procedures at high risk of aerosolization⁽²³⁾.

The levels of PPE have been defined in the literature along with the circumstances in which they should be adhered to^(21,36). Appropriate PPE for the healthcare team in the emergency department and the cath lab are required, regardless of COVID-19 status since history may be limited in these patients⁽²³⁾. Furthermore, proper training of donning and doffing should be provided and practiced by physicians and CCL staff involved in all cases⁽²¹⁾.

Conclusion

As more data becomes available, given the dynamicity of the pandemic, there may be a constant need to reassess the risk-benefit ratio of optimal management strategies across the spectrum of ACS, weighing in the effect of different stages of the pandemic on hospital preparedness and the potential availability of rapid testing. Going forward, it is also imperative that mass public education efforts by means of various media be encouraged, in order to assure patients that healthcare services remain operational and safe for use, especially in case of acute cardiovascular conditions like STEMI, where time-sensitive treatment pathways exist, and delayed presentations could lead to catastrophic consequences.

Acknowledgement

The author acknowledges Professor Luigi P. Badano, Professor of Cardiovascular Medicine, University of Milano-Bicocca, Milano, Italy for his kind permission for use of the infographic on the pathophysiology of the cardio-respiratory effects of SARS-CoV2 infection used in this manuscript.

References

1. WHO Coronavirus Disease (COVID-19) Dashboard: Available at: <https://covid19.who.int/> (Accessed 2nd June 2020)
2. Boukhris M, Hillani A, Moroni F, et al. Cardiovascular implications of the COVID-19 pandemic: a global perspective [published online ahead of print, 2020 May 16]. *Can J Cardiol*. 2020;10.1016/j.cjca.2020.05.018. doi:10.1016/j.cjca.2020.05.018
3. Driggin E, Madhavan MV, Bikdeli B, et al. Cardiovascular Considerations for Patients, Health Care Workers, and Health Systems During the COVID-19 Pandemic. *J Am Coll Cardiol*. 2020;75(18):2352-2371. doi:10.1016/j.jacc.2020.03.031
4. ESC Guidance for the Diagnosis and Management of CV Disease during the COVID-19 Pandemic. Available at: <https://www.escardio.org/Education/COVID-19-and-Cardiology/ESC-COVID-19-Guidance#p03> (Accessed 31st May, 2020)
5. Bansal M. Cardiovascular disease and COVID-19. *Diabetes Metab Syndr*. 2020;14(3):247-250. doi:10.1016/j.dsx.2020.03.013
6. Akhmerov A, Marbán E. COVID-19 and the Heart. *Circ Res*. 2020;126(10):1443-1455. doi:10.1161/CIRCRESA.120.317055



19. Zheng YY, Ma YT, Zhang JY, et al. COVID-19 and the cardiovascular system. *Nat Rev Cardiol*. 2020; 17: 259-260
20. Kwong JC, Schwartz KL, Campitelli MA. Acute Myocardial Infarction after Laboratory-Confirmed Influenza Infection. *N Engl J Med*. 2018; 378: 2538-2541
21. Peiris JS, Chu CM, Cheng VC, et al. Clinical progression and viral load in a community outbreak of coronavirus-associated SARS pneumonia: a prospective study. *Lancet* 2003;361(9371):1767-72. [https://doi.org/10.1016/S0140-6736\(03\)13412-5](https://doi.org/10.1016/S0140-6736(03)13412-5)
22. Tersalvi G, Vicenzi M, Calabretta D, Biasco L, Pedrazzini G, Winterton D. Elevated Troponin in Patients With Coronavirus Disease 2019: Possible Mechanisms [published online ahead of print, 2020 Apr 18]. *J Card Fail*. 2020;S1071-9164(20)30357-2. doi:10.1016/j.cardfail.2020.04.009
23. Chen L, Li X, Chen M, et al. The ACE2 expression in human heart indicates new potential mechanism of heart injury among patients infected with SARS-CoV-2. *Cardiovascular Research* 2020. <https://doi.org/10.1093/cvr/cvaa078>
24. Zhou F, Yu T, Du R, et al. Clinical course and risk factors for mortality of adult inpatients with COVID-19 in Wuhan, China: a retrospective cohort study. *Lancet*. 2020; DOI: 10.1016/S0140-6736(20)30566-3. [epub ahead of print].
25. Madjid M, Safavi-Naeini P, Solomon SD, et al. Potential Effects of Coronaviruses on the Cardiovascular System: A Review [published online ahead of print, 2020 Mar 27]. *JAMA Cardiol*. 2020;10.1001/jamacardio.2020.1286. doi:10.1001/jamacardio.2020.1286
26. Huang C, Wang Y, Li X, et al. Clinical features of patients infected with 2019 novel coronavirus in Wuhan, China. *Lancet*. 2020;395:497-506.
27. Bikdeli B, Madhavan MV, Jimenez D, et al. COVID-19 and Thrombotic or Thromboembolic Disease: Implications for Prevention, Antithrombotic Therapy, and Follow-up. *J Am Coll Cardiol*. 2020 Apr 15:S0735-1097(20)35008-7
28. Libby P, Simon DI. Inflammation and thrombosis: The clot thickens. *Circulation*. 2001;103:1718-1720
29. Thygesen K, Alpert JS, Jaffe AS, et al. Fourth Universal Definition of Myocardial Infarction (2018). *Glob Heart*. 2018;13(4):305-338. doi:10.1016/j.heart.2018.08.004
30. Guo T, Fan Y, Chen M, et al. Cardiovascular Implications of Fatal Outcomes of Patients With Coronavirus Disease 2019 (COVID-19). *JAMA Cardiol* 2020. <https://doi.org/10.1001/jamacardio.2020.1017>
31. Shi S, Qin M, Shen B, et al. Association of Cardiac Injury With Mortality in Hospitalized Patients With COVID-19 in Wuhan, China [published online ahead of print, 2020 Mar 25]. *JAMA Cardiol*. 2020;e200950. doi:10.1001/jamacardio.2020.0950
7. Chapman AR, Bularga A, Mills NL. High-Sensitivity Cardiac Troponin Can Be An Ally in the Fight Against COVID-19 [published online ahead of print, 2020 Apr 6]. *Circulation*. 2020;10.1161/CIRCULATIONAHA.120.047008. doi:10.1161/CIRCULATIONAHA.120.047008
8. Chieffo A, Stefanini GG, Price S, et al. EAPCI Position Statement on Invasive Management of Acute Coronary Syndromes during the COVID-19 pandemic. *Eur Heart J*. 2020;41(19):1839-1851. doi:10.1093/eurheartj/ehaa381
9. Stefanini GG, Montorfano M, Trabattini D, et al. ST-Elevation Myocardial Infarction in Patients with COVID-19: Clinical and Angiographic Outcomes [published online ahead of print, 2020 Apr 30]. *Circulation*. 2020;10.1161/CIRCULATIONAHA.120.047525. doi:10.1161/CIRCULATIONAHA.120.047525
10. Mahmud E, Dauerman HL, Welt FG, et al. Management of Acute Myocardial Infarction During the COVID-19 Pandemic [published online ahead of print, 2020 Apr 21]. *J Am Coll Cardiol*. 2020;S0735-1097(20)35026-9. doi:10.1016/j.jacc.2020.04.039
11. Garcia S, Albaghdadi MS, Meraj PM, et al. Reduction in ST-Segment Elevation Cardiac Catheterization Laboratory Activations in the United States during COVID-19 Pandemic [published online ahead of print, 2020 Apr 9]. *J Am Coll Cardiol*. 2020;S0735-1097(20)34913-5. doi:10.1016/j.jacc.2020.04.011
12. Rodríguez-Leor O, Cid-Álvarez B, Ojeda S, et al. Impact of the COVID-19 pandemic on healthcare activity in interventional cardiology in Spain. *REC Interv Cardiol*. 2020; 2: 82-89
13. Tanner R, MacDaragh Ryan P, Caplice NM. COVID-19- Where Have All the STEMIs Gone? *Can J Cardiol*. 2020 May 1:S0828-282X(20)30429-3. doi: 10.1016/j.cjca.2020.04.032. Epub ahead of print. PMID: 32371004; PMCID: PMC7194038.
14. Bangalore S, Sharma A, Slotwiner A, et al. ST-Segment Elevation in Patients with Covid-19 - A Case Series [published online ahead of print, 2020 Apr 17]. *N Engl J Med*. 2020;NEJMc2009020. doi:10.1056/NEJMc2009020
15. Deshpande A, Birnbaum Y. ST-segment elevation: Distinguishing ST elevation myocardial infarction from ST elevation secondary to nonischemic etiologies. *World J Cardiol*. 2014;6(10):1067-1079. doi:10.4330/wjc.v6.i10.1067
16. Dominguez-Erquicia P, Dobarro D, Raposeiras-Roubín S, Bastos-Fernandez G, Iñiguez-Romo A. Multivessel coronary thrombosis in a patient with COVID-19 pneumonia, *European Heart Journal*, ehaa393, <https://doi.org/10.1093/eurheartj/ehaa393>
17. Minhas AS, Scheel P, Garibaldi B, et al. Takotsubo Syndrome in the Setting of COVID-19 Infection [published online ahead of print, 2020 May 1]. *JACC Case Rep*. 2020;10.1016/j.jaccas.2020.04.023. doi:10.1016/j.jaccas.2020.04.023
18. Sala S, Peretto G, Gramegna M, et al. Acute myocarditis presenting as a reverse Tako-Tsubo syndrome in a patient with SARS-CoV-2 respiratory infection, *Eur Heart J* 2020; 41(19): 1861-1862, <https://doi.org/10.1093/eurheartj/ehaa286>



32. Study: COVID ACS Registry.
https://www.rcbweb.com/COVIDACSREG_de2/login.aspx?ReturnUrl=%2fCOVIDACSREG_de2%2f
(Accessed on 1st June 2020)
33. Jing ZC, Zhu HD, Yan XW, et al. Recommendations from the Peking Union Medical College Hospital for the management of acute myocardial infarction during the COVID-19 outbreak. *Eur Heart J.* 2020;41(19):1791-1794.
doi:10.1093/eurheartj/ehaa258
34. Han Y, Zeng H, Jiang H, et al. CSC Expert Consensus on Principles of Clinical Management of Patients with Severe Emergent Cardiovascular Diseases during the COVID-19 Epidemic. *Circulation.* 2020 Mar 27. doi: 10.1161/CIRCULATIONAHA.120.047011.
35. Daniels MJ, Cohen MG., Bavry AA, et al. Reperfusion of STEMI in the COVID-19 Era – Business as Usual?. *Circulation.* 2020. 10.1161/CIRCULATIONAHA.120.047122
36. Kerkar PG, Naik N, Alexander T, et al. Cardiological Society of India: Document on Acute MI care during COVID-19. *Indian Heart J.* 2020 May 6. doi: 10.1016/j.ihj.2020.04.009. Epub ahead of print. PMID: PMC7201231.
37. Speciality guides for patient management during the coronavirus pandemic. Clinical guide for the management of cardiology patients during the coronavirus pandemic 20 March 2020 Version 1. <https://www.england.nhs.uk/coronavirus/wp-content/uploads/sites/52/2020/03/specialty-guide-cardiology-coronavirus-v1-20-march.pdf> (Accessed on 11th April 2020)
38. Zhang L, Fan Y, Lu Z. Experiences and lesson strategies for cardiology from the COVID-19 outbreak in Wuhan, China, by 'on the scene' cardiologists. *Eur Heart J.* 2020;41(19):1788-1790.
doi:10.1093/eurheartj/ehaa266
39. Figure legend: Figure 1: Pathophysiology of the cardio-respiratory effects of SARS-CoV2 infection Infographic with kind permission of Professor Luigi P. Badano, Professor of Cardiovascular Medicine, University of Milano-Bicocca, Milano, Italy.



Updates

Rapid Journal Scan

From the Editorial desk

A comprehensive analysis of the effects of rivaroxaban on stroke or transient ischaemic attack in patients with heart failure, coronary artery disease, and sinus rhythm: the COMMANDER HF trial

Mandeep R. Mehra et al.
European Heart Journal (2019) 40, 3593–3602

Stroke is often a devastating event among patients with heart failure with reduced ejection (HFrEF).

In COMMANDER HF, rivaroxaban 2.5 mg b.i.d. did not reduce the composite of first occurrence of death, stroke, or myocardial infarction compared with placebo in patients with HFrEF, coronary artery disease (CAD), and sinus rhythm. The study examines the incidence, timing, type, severity, and predictors of stroke or a transient ischaemic attack (TIA), and seek to establish the net clinical benefit of treatment with low-dose rivaroxaban.

In this double-blind, randomized trial, 5022 patients who had HFrEF (<40%), elevated natriuretic peptides, CAD, and who were in sinus rhythm were treated with rivaroxaban 2.5 mg b.i.d. or placebo in addition to antiplatelet therapy, after an episode of worsening HF.

Conclusions

Patients with HFrEF and CAD are at risk for stroke or TIA in the period following an episode of worsening heart failure in the absence of atrial fibrillation. Most strokes are of ischaemic origin and nearly half are either disabling or fatal. **Rivaroxaban at a dose of 2.5 mg b.i.d. reduced rates of stroke or TIA compared with placebo in this population.**

Iron deficiency in worsening heart failure is associated with reduced estimated protein intake, fluid retention, inflammation, and antiplatelet use.

Haye H. van der Wa et al.
European Heart Journal (2019) 40, 3616–3625

Iron deficiency (ID) is common in heart failure (HF) patients and negatively impacts symptoms and prognosis. The aetiology of ID in HF is largely unknown. This study investigated determinants and the biomarker profile of ID in a large international HF cohort.

The data suggest that the **aetiology of ID in worsening HF is complex, multifactorial** and seems to consist of a combination of reduced iron uptake (malnutrition, fluid overload), impaired iron storage (inflammation, chronic kidney disease), and iron loss (antiplatelets).

What is the optimal blood pressure? Differences between current guidelines and novel insights into kidney injury

Thomas F. Lüscher.
European Heart Journal (2019) 40, 3443–3446

Guidelines are highly important, and the European Society of Cardiology and European Society of Hypertension (ESC/ESH), as well as their US counterparts regularly publish such guidelines.

Whilst agreeing on many points, there are also important differences in the recommendations of these three guidelines, one such difference being the target blood pressures which are 120 mmHg systolic in the US Guidelines, 120–129 mmHg for younger and 130–139 mmHg systolic for elderly hypertensives in the ESC Guidelines, and still 140/90 mmHg in the conservative NICE Guidelines (Table 1).

The kidney is a major target organ of damage in HT.



Thus, biomarkers of kidney tubule injury, inflammation, and fibrosis have been studied extensively and suggested to be associated with cardiovascular outcomes.

The article entitled 'Markers of kidney tubule function and risk of cardiovascular disease events and mortality in the SPRINT trial investigated this issue in more depth in 2377 hypertensives with chronic kidney disease of the SPRINT trial. association.

where tolerated, that systolic blood pressure (SBP) for those aged under 65 should be reduced to between 120 and 129 mmHg.

The updated NICE guideline continues to recommend treating to a threshold and target BP of 140/90 mmHg, as opposed to the lower treatment targets recommended by the ESC/ESH.

To understand how such differences can occur between the NICE and ESC/ESH guidelines, it is necessary to recognize that they use two different processes with different aims and methods.

Updates

Table 1 Ten specific areas in each hypertension guideline (from McCormack T, Boffa RJ, Jones NR, Carville S, McManus RJ. The 2018 ESC/ESH hypertension guideline and the 2019 NICE hypertension guideline, how and why they differ. See pages 3456–3458).

	ESC/ESH 2018	NICE 2019
Diagnosis of hypertension using office measurements of blood pressure	≥140/90 mmHg	≥140/90 mmHg
Start medication in grade/stage 1 hypertension when;	Lifestyle has failed to control blood pressure and there is low/moderate risk	Risk ≥10% and lifestyle interventions have failed
Number of drugs used to initiate treatment	Two unless systolic blood pressure is <150 mmHg or the patient is frail	One
Single pill combination therapy	Use two or three medication single pills	No recommendation
Office systolic blood pressure target for those aged 18 to 64	<120 – 129 mmHg	<140 mmHg
Office systolic blood pressure target for those aged 65 to 69	<130 – 139 mmHg	<140 mmHg
Office systolic blood pressure target for those aged ≥ 80	<130 – 139 mmHg	<150 mmHg
Office diastolic blood pressure target	<80 mmHg	<90 mmHg
Threshold to treat blood pressure in people with diabetes using office measurements	≥140/90 mmHg	≥140/90 mmHg
Office blood pressure target in people with diabetes	<130/80 mmHg	<140/90 mmHg

With thanks to Amelia Meier-Batschelet for help with compilation of this article.

Published on behalf of the European Society of Cardiology. All rights reserved. © The Author(s) 2019. For permissions please email: journals.permissions@oup.com.

Unadjusted, α_1 and β_2 microglobulin had positive associations with major cardiovascular events (MACE), whereas uromodulin had an inverse association.

In multivariate analysis including estimated glomerular filtration rate (eGFR) and albuminuria, a two-fold higher baseline concentration of α_1 microglobulin was associated with higher risk of MACE and mortality, whereas β_2 microglobulin had no associations.

A two-fold higher uromodulin concentration was associated with lower MACE, with a hazard ratio of 0.79, but not mortality after adjusting for confounders.

The ESC/ESH guidelines reiterate the importance of reducing blood pressure (BP) below 140/90 mmHg for all patients, but go further to suggest,

NICE produces government-funded national guidelines intended for population treatment based on both clinical evidence and cost-effective analysis. NICE start with a series of questions, which can be quite specific, based on feedback from a broad range of stakeholders. ESC and ESH are medical societies who fund the clinical guideline development, with a broad scope, intended for treatment of individuals in many European countries with different socio-economic populations.

The evidence base and its interpretation also differed within each guideline, which had implications for recommendations. This fundamental difference in interpretation is exemplified by the SPRINT trial.



NICE considered that the methodology of measuring BP could not be translated into UK clinical practice and so did not lower the recommended treatment target. The use of automated devices set on a time delay, with an unaccompanied rest period, is not common practice in the UK and was considered likely to result in significantly lower BP readings than those taken in routine clinical practice.

Gender in cardiovascular medicine: chest pain and coronary artery disease

Puja K Mehta et al.
European Heart Journal (2019) 40, 3819–3826

Ischaemic heart disease (IHD) remains the leading cause of morbidity and mortality among women and men yet women are more often underdiagnosed, have a delay in diagnosis, and/or receive suboptimal treatment.

An implicit gender-bias with regard to lack of recognition of sex-related differences in presentation of IHD may, in part, explain these differences in women compared with men.

Existing knowledge demonstrates that angina does not commonly relate to obstructive coronary artery disease (CAD). Emerging knowledge supports an inclusive approach to chest pain symptoms in women, as well as a more thoughtful consideration of percutaneous coronary intervention for angina in stable obstructive CAD, to avoid chasing our tails.

Emerging knowledge regarding the cardiac autonomic nervous system and visceral pain pathways in patients with and without obstructive CAD offers explanatory mechanisms for angina.

Interdisciplinary investigation approaches that involve cardiologists, biobehavioural specialists, and anaesthesia/pain specialists to improve angina treatment should be pursued.

Sex differences in heart failure

Carolyn S P Lam et al.
European Heart Journal (2019) 40, 3859–3868

The overall lifetime risk of heart failure (HF) is similar between men and women, however, there are marked sex differences in the landscape of this condition that are both important and under-recognized.

Men are predisposed to HF with reduced ejection fraction (HFrEF), whereas women predominate in HF with preserved ejection fraction (HFpEF).

Sex differences are also notable in the penetrance of genetic cardiomyopathies, risk factors, e.g. breast cancer which may be associated with cancer treatment-induced cardiomyopathy, as well as sex-specific conditions such as peripartum cardiomyopathy (PPCM).

A central hypothesis is that the higher risk of HFrEF in men compared to women may be attributable to their **predisposition to macrovascular coronary artery disease and myocardial infarction, whereas coronary microvascular dysfunction/endothelial inflammation** has been postulated to play a key role in HFpEF and maybe the common link among HF syndromes that women are predisposed to Takotsubo cardiomyopathy, PPCM, and breast cancer radiotherapy-induced cardiomyopathy.

Under-pinning current sex disparities in HF, there is a paucity of women recruited to HF clinical trials (20–25% of cohorts) and thus treatment guidelines are predominantly based on male-derived data.

Large gaps in knowledge exist in sex-specific mechanisms, optimal drug doses for women and sex-specific criteria for device therapy.



The COMPLETE (COMPLETE Revascularization with Multivessel Percutaneous Coronary Intervention in ST-segment Elevation Myocardial Infarction) trial.

ESC Congress 2019

The international randomized COMPLETE trial showed that complete revascularization reduces major cardiovascular events, compared to culprit-lesion only PCI.

About half of patients with ST-segment elevation myocardial infarction (STEMI) have multivessel coronary artery disease (CAD). This means that in addition to the culprit artery, they have additional stenosed (non-culprit) coronary arteries. In STEMI patients, opening the culprit artery with PCI reduces cardiovascular death or myocardial infarction. It is unclear whether additional PCI of non-culprit lesions also prevents these events. ‘The question of whether to routinely revascularize non-culprit lesions or manage them conservatively with guideline-directed medical therapy alone is a common dilemma’.

For the study, 4041 patients with STEMI and multivessel CAD were enrolled from 140 centres in 31 countries with patients randomly allocated to complete revascularization with additional PCI of angiographically significant non-culprit lesions, or to no further revascularization. At a median follow-up of 3 years, the first coprimary outcome of cardiovascular death or myocardial infarction occurred in 158 patients (7.8%) in the complete revascularization group compared to 213 (10.5%) in the culprit-lesion only group. The second coprimary outcome of cardiovascular death, myocardial infarction, or ischaemia-driven revascularization occurred in 179 patients (8.9%) in the complete revascularization group compared to 399 (16.7%) in the culprit-lesion only group.

‘COMPLETE is the first randomized trial to show that complete revascularization reduces hard cardiovascular events compared to culprit-lesion only PCI in patients with STEMI and multivessel coronary artery disease.

NZOTACS—New Zealand Oxygen Therapy in Acute Coronary Syndromes trial

ESC Congress 2019

The role—and benefits or harm—of oxygen in acute coronary syndrome has been uncertain, with ESC guidelines recommending oxygen in patients with STEMI and non-STEMI when blood oxygen saturation is below 90%, but not routinely above this level. Additionally, the possibility of harm in non-hypoxaemic patients was raised by a 2018 meta-analysis.

The aim of the New Zealand Oxygen Therapy in Acute Coronary Syndromes (NZOTACS) trial was to identify or exclude modest favorable or adverse effects of oxygen in non-hypoxaemic or mildly hypoxaemic patients with a suspected or confirmed acute coronary syndrome.

The cluster randomized crossover trial compared two oxygen protocols as part of routine care in 40 872 patients over 2 years. The primary endpoint was 30-day mortality obtained from a national database. For all patients, 30-day mortality was the same with the high and low oxygen protocols (3.1% vs. 3.0%).

Principal investigator Professor Ralph Stewart of Green Lane Cardiovascular Service, Auckland City Hospital, New Zealand, said: ‘This suggests that oxygen is neither beneficial nor harmful, and it is safe to give oxygen to patients presenting with a suspected or confirmed acute coronary syndrome’. For patients with STEMI, 30-day mortality was significantly decreased with the high compared to the low oxygen protocol (8.8% vs. 10.6%). However, Prof. Stewart added that while oxygen may benefit patients presenting with STEMI, who have the most severe myocardial ischaemia and the highest mortality, more evidence is needed to be sure.

updates



Safety and efficacy outcomes of double vs. triple antithrombotic therapy in patients with atrial fibrillation following percutaneous coronary intervention: a systematic review and meta-analysis of non-vitamin K antagonist oral anticoagulant-based randomized clinical trials

Giuseppe Gargiulo et al.
European Heart Journal (2019) 40, 3757–3767

Aims were to investigate the safety and efficacy of double vs. triple antithrombotic therapy (DAT vs. TAT) in patients with atrial fibrillation (AF) and acute coronary syndrome or who underwent percutaneous coronary intervention (PCI).

A systematic review and meta-analysis was performed using PubMed to search for non-vitamin K antagonist oral anticoagulant (NOAC)-based randomized clinical trials comparing DAT vs. TAT in AF patients undergoing PCI.

The primary safety endpoint (ISTH major or clinically relevant non-major bleeding) was significantly lower with DAT compared with TAT, which was consistent across all available bleeding definitions. This benefit was counterbalanced by a significant increase of stent thrombosis and a trend towards higher risk of myocardial infarction with DAT. There were no significant differences in all-cause and cardiovascular death, stroke and major adverse cardiovascular events.

Conclusion Double antithrombotic therapy, particularly if consisting of a NOAC instead of VKA and a P2Y12 inhibitor, is associated with a reduction of bleeding, including major and intracranial haemorrhages. This benefit is however Counterbalanced by a higher risk of cardiac mainly stent-related but not cerebrovascular ischaemic occurrences.

Transcatheter Aortic Valve Implantation vs. Surgical Aortic Valve Replacement for Treatment of Symptomatic Severe Aortic Stenosis: An Updated Meta-Analysis.

George C M Siontis
European Heart Journal (2019) 40, 3143-3153.

Owing to new evidence from randomized controlled trials (RCTs) in low-risk patients with severe aortic stenosis, this study compared the collective safety and efficacy of trans-catheter aortic valve implantation (TAVI) vs. surgical aortic valve replacement (SAVR) across the entire spectrum of surgical risk patients.

Conclusion: Compared with SAVR, TAVI is associated with reduction in all-cause mortality and stroke up to 2 years irrespective of baseline surgical risk and type of THV system.

Impact of long-term ticagrelor monotherapy following 1-month dual antiplatelet therapy in patients who underwent complex percutaneous coronary intervention: insights from the Global Leaders trial

Patrick W. Serruys et al.
European Heart Journal (2019) 40, 2595–2604

Aims were to evaluate the impact of an experimental strategy [23-month ticagrelor monotherapy following 1-month dual antiplatelet therapy (DAPT)] vs. a reference regimen (12-month aspirin monotherapy following 12-month DAPT) after complex percutaneous coronary intervention (PCI).

Conclusion was that **ticagrelor monotherapy following 1-month DAPT could provide a net clinical benefit for patients with complex PCI.** However, in view of the overall neutral results of the trial, these findings of a post hoc analysis should be considered as hypothesis generating.



Defining High Bleeding Risk (HBR) in Patients Undergoing Percutaneous Coronary Intervention:- A Consensus Document From the Academic Research Consortium for High Bleeding Risk

Philip Urban et al.
European Heart Journal (2019) 40, 2632–2653

Identification and management of patients at high bleeding risk undergoing percutaneous coronary intervention are of major importance, but a lack of standardization in defining this population limits trial design, data interpretation, and clinical decision-making.

A consensus definition of patients at high bleeding risk was developed that was based on review of the available evidence.

Table 3. Major and Minor Criteria for HBR at the Time of PCI

Major	Minor
	Age ≥ 75 y
Anticipated use of long-term oral anticoagulation*	
Severe or end-stage CKD (eGFR <30 mL/min)	Moderate CKD (eGFR 30–59 mL/min)
Hemoglobin <11 g/dL	Hemoglobin 11–12.9 g/dL for men and 11–11.9 g/dL for women
Spontaneous bleeding requiring hospitalization or transfusion in the past 6 mo or at any time, if recurrent	Spontaneous bleeding requiring hospitalization or transfusion within the past 12 mo not meeting the major criterion
Moderate or severe baseline thrombocytopenia† (platelet count $<100 \times 10^9/L$)	
Chronic bleeding diathesis	
Liver cirrhosis with portal hypertension	
	Long-term use of oral NSAIDs or steroids
Active malignancy‡ (excluding nonmelanoma skin cancer) within the past 12 mo	
Previous spontaneous ICH (at any time)	Any ischemic stroke at any time not meeting the major criterion
Previous traumatic ICH within the past 12 mo	
Presence of a bAVM	
Moderate or severe ischemic stroke§ within the past 6 mo	
Nondeferrable major surgery on DAPT	
Recent major surgery or major trauma within 30 d before PCI	

bAVM indicates brain arteriovenous malformation; CKD, chronic kidney disease; DAPT, dual antiplatelet therapy; eGFR, estimated glomerular filtration rate; HBR, high bleeding risk; ICH, intracranial hemorrhage; NSAID, nonsteroidal anti-inflammatory drug; and PCI, percutaneous coronary intervention.

*This excludes vascular protection doses.⁴²

†Baseline thrombocytopenia is defined as thrombocytopenia before PCI.

‡Active malignancy is defined as diagnosis within 12 months and/or ongoing requirement for treatment (including surgery, chemotherapy, or radiotherapy).

§National Institutes of Health Stroke Scale score ≥ 5 .

Elevated high-density lipoprotein in adolescents with Type 1 diabetes is associated with endothelial dysfunction in the presence of systemic inflammation

Scott T. Chiesa et al.
European Heart Journal (2019) 40, 3559–3566

High-density lipoprotein (HDL) function may be altered in patients with chronic disease, transforming the particle from a beneficial vasoprotective molecule to a noxious pro-inflammatory equivalent. Adolescents with Type 1 diabetes often have elevated HDL, but its vasoprotective properties and relationship to endothelial function have not been assessed.

Seventy adolescents with Type 1 diabetes (age 10–17 years) and 30 age-matched healthy controls was the study population.

HDL-c levels and glycated haemoglobin (HbA1c) were increased in all patients compared with controls. However, increased inflammation and HDL dysfunction were evident only in patients who also had evidence of early renal dysfunction. Endothelial function (FMD) was impaired only in those who had both a high inflammatory risk score and high levels of HDL-c ($P < 0.05$).

Increased levels of HDL-c commonly observed in individuals with Type 1 diabetes may be detrimental to endothelial function when accompanied by renal dysfunction and chronic inflammation.

Dysfunctional HDL and inflammation is a noxious liaison in adolescents with type 1 diabetes

Philipp Jakob et al.
European Heart Journal (2019) 40, 3567–3570

Diabetes mellitus is a key condition that fosters pro-inflammatory, pro-apoptotic, and pro-oxidative properties of HDL particles. Indeed, HDL isolated from both patients with type 2 diabetes and those with T1DM show an impaired anti-inflammatory capacity, despite comparable or even elevated HDL levels in T1DM patients as compared with healthy controls.



Contrary to expectations, the loss of HDL-associated vasculo-protective effects is not confined to HbA1c or poor glycemic control, suggesting that drivers other than elevated glucose levels render HDL dysfunctional. In this respect, inflammation and renal dysfunction have been shown to change the functional and structural properties of HDL.

The neurohormonal basis of pulmonary hypertension in heart failure with preserved ejection fraction

Masaru Obokata et al.
European Heart Journal (2019) 40, 3707–3717

Pulmonary hypertension (PH) represents an important phenotype among the broader spectrum of patients with heart failure with preserved ejection fraction (HFpEF), but its mechanistic basis remains unclear. The authors hypothesized that activation of endothelin and adrenomedullin, two counterregulatory pathways important in the pathophysiology of PH, would be greater in HFpEF patients with worsening PH, and would correlate with the severity of haemodynamic derangements and limitations in aerobic capacity and cardiopulmonary reserve.

Plasma levels of C-terminal pro-endothelin-1 (CT-proET-1) and mid-regional pro-adrenomedullin (MR-proADM), central haemodynamics, echocardiography, and oxygen consumption (VO₂) were measured at rest and during exercise in subjects with invasively-verified HFpEF (n=38) and controls free of HF (n=20) as part of a prospective study.

Conclusion

Subjects with HFpEF display activation of the endothelin and adrenomedullin neurohormonal pathways, the magnitude of which is associated with pulmonary haemodynamic derangements, limitations in RV functional reserve, reduced cardiac output, and more profoundly impaired exercise capacity in HFpEF. Further study is required to evaluate for causal relationships and determine if therapies targeting these counterregulatory pathways can improve outcomes in patients with the HFpEF-PH phenotype.

Cardiovascular effect of discontinuing statins for primary prevention at the age of 75 years: a nationwide population-based cohort study in France

Philippe Giral et al.
European Heart Journal (2019) 40, 3516–3525

The role of statin therapy in primary prevention of cardiovascular disease in persons older than 75 years remains a subject of debate with little evidence to support or exclude the benefit of this treatment. We assessed the effect of statin discontinuation on cardiovascular outcomes in previously adherent 75-year-olds treated for primary prevention.

This was a population-based cohort study using French national healthcare databases was performed, studying all subjects who turned 75 in 2012–14, with no history of cardiovascular disease and with a statin medication possession ratio $\geq 80\%$ in each of the previous 2 years. Statin discontinuation was defined as three consecutive months without exposure.

Statin discontinuation was associated with a 33% increased risk of admission for cardiovascular event in 75-year old primary prevention patients.

Conclusion

The results of this study suggest potential cardiovascular risk reduction associated with continuing statin therapy after the age of 75 years in persons already taking these drugs for primary prevention. However, due to the observational nature of this study, residual confounding cannot be excluded. Future studies, including interventional randomized studies, are needed to confirm these findings and support updating and clarification of guidelines on the use of statins for primary prevention in the elderly.

As seen in the current study, early statin discontinuation was associated with increased risk of MI and CV death. The former US President Bill Clinton actually experienced this. As he did rehab for his knee, he exercised and lost weight, so he stopped his statin, but a few months later developed unstable angina and required coronary bypass surgery.



We can contrast with aspirin for primary prevention, where recent trials have shown increased bleeding and no benefit in the elderly.¹⁴ An editorialist on one of these recent aspirin studies, Dr. Paul Ridker, concluded ‘Thus, beyond diet maintenance, exercise, and smoking cessation, the best strategy for the use of aspirin in the primary prevention of cardiovascular disease may simply be to prescribe a statin instead’.

Mortality reduction with physical activity in patients with and without cardiovascular disease

Sang-Woo Jeong et al.
European Heart Journal (2019) 40, 3547–3555

Physical activity has been shown to reduce mortality in a dose-response fashion. Current guidelines recommend 500–1000 metabolic equivalent task (MET)-min per week of regular physical activity. This study aimed to compare the impact of leisure-time physical activity on mortality in primary versus secondary cardiovascular prevention.

This study included a total of 131 558 and 310 240 subjects with and without cardiovascular disease (CVD), respectively, from a population-based cohort. Leisure-time physical activity was measured by self-report questionnaires. The study subjects were followed-up for a median of 5.9 years, and the main study outcome was all-cause mortality. There was an inverse relationship between the physical activity level and the mortality risk in both groups.

The benefit in the secondary prevention group was shown to be greater than that in the primary prevention group: every 500 MET-min/week increase in physical activity resulted in a 14% and 7% risk reduction in mortality in the secondary and primary prevention groups, respectively (interaction $P < 0.001$).

In addition, while individuals without CVD benefited the most between 1 and 500 MET-min/week of physical activity, the benefit in those with CVD continued above 500 - 1000 MET-min/week. The adjusted mortality risk of individuals with CVD who performed a high level of physical activity (> 1000 MET-min/week) was shown to be comparable to or lower than that of their counterparts without CVD.

Conclusion

Individuals with CVD may benefit from physical activity to a greater extent than do healthy subjects without CVD.

This study from Korea is certainly limited by the fact that this Asian population generally had much better overall CVD profiles and markedly lower body mass indices and prevalence of obesity than similar populations in the USA and most of Europe. Also, this study analyzed only leisure-time physical activity, which was self-reported. This is in contrast to the emphasis in recent guidelines which focus on all forms of physical activity (household management, transportation, etc., in addition to leisure-time physical activity) in any time intervals (not just done in 10-min intervals for CVD prevention).

Although not ensure-time physical activity and cardiorespiratory fitness are associated with substantial CVD protection, most studies demonstrated that cardiorespiratory fitness is considerably more powerful than physical activity for protecting against CVD risk and mortality.

Finally there is now evidence that demonstrates not only that physical activity/leisure-time physical activity is important, but also that limiting sedentary behavior and physical inactivity is also extremely important for CVD protection, even independently of physical activity.



COVID -19 Basics for Cardiologists

From the editorial desk

Tutorial

1. What do the terms COVID 19 and SARS-COV-2 signify?

The virus is called COVID-19.

The syndrome caused by it is called SARS-COV-2. (SARS - Severe acute respiratory syndrome)

The virus is a single stranded RNA virus.

It can survive on metal, glass and plastic surfaces for a few days. Toys, utensils and mobile phones fall into this category.

The virus can survive on cardboard, paper and cotton clothing for a few days. Books, magazines and paper money fall into this category.

Latex rubber gloves are not protective as the virus can survive on them for few days.

The virus can last on ceramic ware, steel ware and wood for few days. Door handles, taps, coins, cupboard doors etc. fall into this category.

The term 'a few days' in the text above refers to the long range of 3-9 days. This long range is given in order to cover all published studies but 3days is the usual period of survival.

The virus survives for 3 hours in the droplets coughed out into air. (Now it is thought that even normal talking can cause emission of such droplets).

The emission of droplets is higher when you talk forcefully in a noisy crowded area or in a loud music background. Emission is also probably higher when you sing aloud compared to quiet talking.

Small droplets of 1-5 μm in diameter can float in the air for 3 hours (and sometimes longer). These are called aerosols.

If the atmosphere temperature is low, the virus can persist as aerosol for 28 days.

New data suggests that the virus can be excreted in the feces of a patient for weeks. Hence good personal hygiene is essential for all patients and close associates.

Washing with soap and water for 20 seconds eliminates the virus.

Alcohol solutions (of 62-71%) will also eliminate the virus in 20 seconds. (However for both the above, a time period of 1 minute is suggested if contamination is likely).

Much of the knowledge regarding COVID 19 virus is still unconfirmed. Hence the above facts might be revised with further insight into the virus.

2. Why was the safety of ACE-I and ARBs queried in SARS-COV-2 patients?

The COVID- 19 virus is single standard RNA enveloped virus which has a structural spike (s) protein which binds to the angiotensin converting enzyme 2 (ACE 2) on cell membranes. After binding to the ACE 2 the virus enters the cell. (At present we know of no other way the virus can enter a human cell).

3. What is ACE 2?

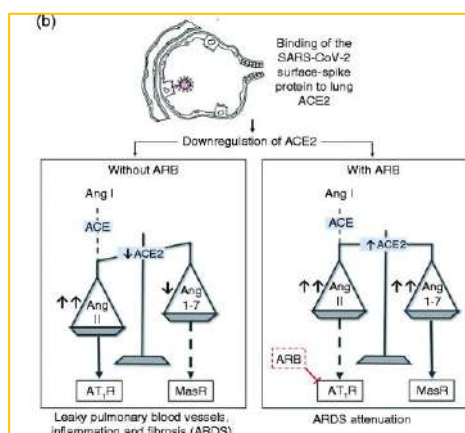
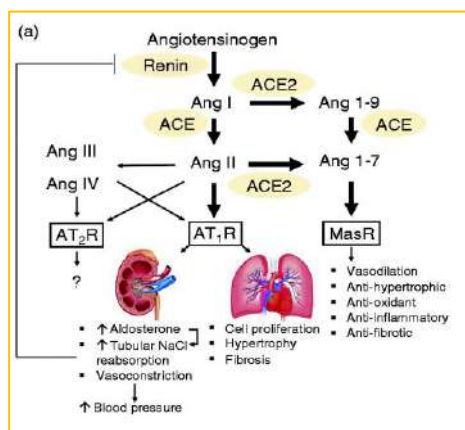
This is a member of the ACE family. (These are dipeptidyl carboxy dipeptidases). Angiotensin converting enzyme 2 (ACE 2) is a close homolog of the angiotensin converting enzyme commonly called ACE. (which is blocked by the ACE inhibitor drugs).

The actions of ACE and ACE 2 are different.

- ACE cleaves angiotensin I to angiotensin II. The angiotensin I binds to angiotensin receptor 1 (AT-1R) which causes vasoconstriction and other effects which lead to hypertension.
- ACE 2 cleaves angiotensin II and generates angiotensin. This is a potent vasodilator and also has anti-hypertrophic and anti-inflammatory actions all of which are beneficial.



- ACE 2 is a membrane protein (found on cells of the lung, liver, testes, heart, kidney and intestine).
- ACE 2 expression is increased in HT, HF as a protective mechanism.
- Use of ARB blockers increases ACE 2 expression.
- Use of ACE-I may increase ACE 2 expression but this is controversial.



AT1R: angiotensin II type 1 receptor; AT2R: angiotensin II type 2 receptor; MasR: Mas receptor; SARS-CoV-2: severe acute respiratory syndrome coronavirus 2.

European Journal of Preventive Cardiology 0(0) 1–4
©The European Society of Cardiology 2020

4. Where do you find ACE 2?

We find it in most tissues but it is highly expressed in the lung and heart. A high density of the ACE 2 is also found in the;

- intestine
- kidney
- blood vessels.

5. What will happen to the ACE system with COVID infection?

The COVID virus will bind to ACE 2. This will affect the ACE / ACE 2 balance so that there will be heightened angiotensin II activity. This will lead to;

1. pulmonary vasoconstriction
2. pulmonary inflammation
3. oxidative organ (lung) damage

You may even postulate that the use of ACE-I or ARB may lead to a mitigation of these deleterious effects of angiotensin II.

But guidelines so far recommend the use of ACE-I /ARB, ONLY for definite indications such as hypertension, heart failure and diabetes.

6. What happens to ACE 2 when you treat with ACE-I?

ACE inhibitors decrease levels of angiotensin II. Hence there is an indirect upregulation of ACE 2 protein. (Angiotensin II is known to reduce ACE 2 expression).

Theoretically, patients on ACE-I will have a greater number of ACE 2 protein on the cell membrane, through which viral particles can enter into human cells.

This is why ACE I were first suggested to be inappropriate in COVID 19 infections.

7. What happens to ACE 2 when you treat with ARBs?

The clinically used ARBs are angiotensin I receptor blockers.

ARBs augment free angiotensin II levels and hence, theoretically at least, can lead to a reduction in ACE-2 protein density. This will be beneficial in COVID 19 infections.



8. Do we need to omit the ACE-I and ARB in patients already on them?

The current evidence based recommendation is that these drugs may be continued when used as guide line based therapy for another disease such as HT, Heart failure, diabetes mellitus etc.

9. What is the status of neprilysin O inhibitor + angiotensin II receptor blocker combination (sacubitril / valsartan) in SARS-COV-2 ?

Because the COVID 19 virus uses the ACE 2 as a receptor to bind to the cell membrane, in SARS - COV-2 the ACE 2 levels are down regulated – so that there is an increase in the production of angiotensin. In this scenario sacubitril / valsartan combination can be beneficial.

Hence it can be continued in COVID 19 infections.

10. How do I interpret the troponin I results in COVID 19 infected patients?

HS/Troponin I levels are elevated in most COVID-19 positive patients. Significant rises are seen in more than 50% of patients who die of COVID-19. As the myocardium has a rich content of ACE 2 to which COVID 19 binds, it's quite possible that myocardial damage occurs leading to HS-Troponin elevation.

11. What are the usual troponin levels expected in SARS COV-2?

On admission (ie onset of symptoms):-

In survivors	-	.0025ng/ml
In non survivors	-	.0088ng/ml

During follow-up:-

In survivors	-	.0025-.0044 ng/ml
In non survivors	-	.25ng/ml and more

These values are mere approximations derived from a single study.

12. How can I use troponin I levels to diagnose an acute coronary even in SARS COV 2 patients?

Because troponin rise is mostly 'non specific' in COVID 19' patients do not routinely assay the troponin unless:

- clinical judgment
- symptoms and signs
- ECG changes

Suggest incident cardiac pathology.

Do not diagnose cardiac pathology based on the troponin levels alone. Always use clinical judgment, clinical features of ECG changes and echo findings to diagnose any cardiac involvement.

Even a rising titre of troponin will be non-diagnostic in SARS-COV-2 unless other features confirm the diagnose of ACS.

Note :- Do NOT routinely do troponin I testing in COVID 19 infection.

This will only lead to increased 'downstream testing' such as CT coronary angiography, invasive angiography, cardiac nuclear studies and cardiac MRI studies etc.. all of which are out of the sphere of rational medicine in managing SARS-COV-2.

13. What happens to BNP levels in COVID-19?

In many respiratory illnesses of some degree of severity, BNP levels can rise- even though the LV filling pressures are normal and there are no clinical features of heart failure.

However, in ARDs, a rise in BNP signifies a bad prognosis.

In COVID 19 positive patients too, BNP levels are commonly elevated. This must not be construed as heart failure without other clinical features and echo cardiographic evidence of LV dysfunction.



14. What mechanisms can explain the rise in biomarkers in SARS COV2 patients?

1. Direct viral damage of the myocytes.
2. Secondary damage due to hypoxia.
3. Systemic inflammation due to cytokine storm.

15. Do troponin and BNP levels have a value in prognostication?

Yes: Both these cardiac markers signify a worse prognosis specially if significantly elevated.

They can therefore be useful for prognostication but not for firm diagnosis of ACS or heart failure.

16. What pathological processes can cause HF in SARS COV-2?

1. Viral myocarditis
2. Stress cardiomyopathy
3. Cytokine induced cardiomyopathy due to cytokines storm. This is important to keep in mind as dexamethasone will help these patients.

17. Can a Brugada type ECG be seen in SARS-COV-2?

Remember that Brugada syndrome can be unmasked in COVID 19 infections as in any febrile illness.

18. What cardiac syndromes can occur in SARS- COV 2?

1. Viral myocarditis
2. Stress cardiomyopathy (typical takotsubo)
3. Acute coronary syndrome
4. Atrial fibrillation, VT, heart block and other arrhythmias too

19. What co-morbidities affect COVID mortality?

Mortality is higher in

- diabetics
- hypertensives

These patients tend to develop a high density of ACE 2 as a protective mechanism. This stands against them in COVID 19 infections.

Hence cardiologists have to be vigilant in care of these patients.

20. How did chloroquine and hydroxychloroquine enter the COVID discussion?

These drugs have been used for a long time in managing malaria, SLE and rheumatoid arthritis.

These drugs affect host receptors, by various chemical means and there by retard virus entry in cells.

Although initial small studies were promising, good data on the efficacy of these drugs in COVID 19 is lacking.

The interest to the Cardiologist is that these drugs cause prolongation of the QT interval.

Correctly, the QTc must be measured before administration these drugs for COVID patients.

However experienced physicians say that they never checked / check QTc when using these drugs for malaria.

21. Is it safe to combine hydroxy-chloroquine with azithromycin for COVID 19 patients?

This combination is no longer used. Both these drugs prolong the QTc and combination of the two may lead to cardiac emergencies.



22. Can antiplatelet agents and anticoagulants be used in SARS-COV-2?

Thrombosis is probably common in COVID-19 infection due to

- excessive inflammation
- activation of platelets
- endothelial dysfunction
- blood stasis

The thrombotic process can occur in both arterial and venous systems with organ ischaemia and distal embolization.

Hence all patients already on antiplatelet agents and anti-coagulants must continue on same if they get infected with COVID 19.

Prophylaxis for venous thrombo embolism (VTE) must not be routinely given in SARS-COV-2. You need to follow the standard guidelines for this.

Prophylaxis for arterial and venous thrombosis is given only if there is an incident episode of thrombosis or the risk for thrombosis is very high.

Both heparin and enoxaparin can be used in SARS-COV-2 as per usual guidelines.

23. Can amiodarone and verapamil be used in COVID-19 patients?

Once the virus binds to the ACE 2, it enters the cell by endocytosis.

Once within the cell the virus genome is released into the host cytoplasm. This involves a long process which apparently needs an acidic pH.

Drugs which are called cationic amphiphilic drugs (CAD) reduce the acidic pH of the cell. These drugs will therefore help retard viral proliferation once inside the cell.

CADs are-

- amiodarone
- dronedarone
- verapamil

Hence these drugs can be used by the cardiologist to treat arrhythmias in COVID-19 infections.

24. What are the basic preventive measures to be taken by cardiologists?

1. Limit face to face contact:-

- Hence try to conduct virtual clinics.
In Sri Lanka the audio consultation with the help of Viber or WhatsApp is best as it is accessible for most people.
- Auscultate minimally
- Limit 2Decho study to LV function only
- Use once a day enoxaparin dosage to avoid going near the patient too frequently.

2. Avoid non urgent procedures.

Do not hesitate for an invasive procedure in

- STEMI
- Very high risk and high risk NSTEMI
- Out of hospital cardiac arrest needs an invasive procedure only if a STEMI is present on ECG.
- Permanent pacing is to be done only for symptomatic 3^o, 2^o heart blocks or severe SSS.
- Have a 'Hot' or Dirty Cath lab / theater dedicated for COVID patients.
- For management of a cardiac arrest where face-to-face contact cannot be minimized, full *aerosol generating procedure* PPE must be worn.

25. Is heparin safe in covid-19?

Heparin binds onto the spike protein of cell membranes and thus may prevent the virus entering. It may be used with the usual precautions.



Case Report

A case series of Left Atrial Appendage (LAA) Device closure in Sri Lanka

Ranasinghe WG¹, Shetty R², Paul VE³, Ponnampereuma CJ¹, Paranamana RS¹, Karunaratne S¹, Vithanage TDP¹, Colombage DDE¹, Sajeev S¹, Sovis WFRD¹, Jayasinghe VP¹, Liyanage HTRP¹

1. Institute of Cardiology, National Hospital of Sri Lanka

2. Department of Cardiology, Kasturba Medical College, Manipal

3. Royal Perth Hospital, Australia

Corresponding author: Dr. Gotabhaya Ranasinghe, Consultant Cardiologist

E-mail: gotabhayar@gmail.com

Abstract

Ischaemic stroke is a major complication in atrial fibrillation (AF) due to cardiac emboli. Most cardiac emboli in AF arise from the left atrial appendage (LAA).

Oral anticoagulant (OAC) is widely used for stroke prevention in patients with risk of stroke in AF and the commonly used drug is warfarin. Some patients may have contraindications, complications, intolerance and poor compliance to OAC. Percutaneous LAA device closure is an evolving procedure which mechanically occludes the LAA reducing the usage of OAC and also stroke events by preventing thrombus formation in the LAA. It is now recommended in guidelines for stroke prevention in patients with AF who are unable to take warfarin. LAA device closure is non-inferior to OAC in stroke prevention.

Key words: Atrial fibrillation, Left atrial appendage, Stroke, Oral anticoagulation

Introduction

In patients with atrial fibrillation (AF), an ischaemic stroke may occur as the initial presenting manifestation due to formation of a cardiac thrombus. Any form of AF (i.e. paroxysmal, persistent, or permanent) can lead to development and subsequent embolization of atrial thrombi. Cardiac thrombi originating from the LAA is the common cause (>90%) of ischaemic stroke in AF patients ^(1,2). LAA is a muscular pouch connected to the left atrium (LA) of the heart. In AF patients, fibrosis and inflammation seen in the LA are particularly intense in the LAA and fibrillating LAA is the only area within the left atrium that comprise of pectinate muscle and can create an appropriate milieu for blood stasis and thrombus formation.

Patients with non-valvular AF and high risk for ischaemic stroke (CHA₂DS₂ VASc >2) should be on an oral anticoagulant (OAC) for stroke prevention. LAA device closure is an option for patients who have clear contraindications, poor compliance and are intolerant to OAC.

Case series

We selected four patients with non-valvular AF (rate controlled) with CHA₂DS₂ VASc Score > 2 for this case series at Institute of Cardiology in National Hospital of Sri Lanka on 9th November 2019.

First patient was a 31 year old male navy officer who was unable to take warfarin due to his occupational risks of trauma and failed radiofrequency ablation; second patient was a 71 year-old diagnosed patient with oesophageal varices who had episodes of haematemesis; third patient was a 51 year-old female with poor compliance to OAC and erratic INR and fourth patient was a 69 year old male patient with a history of a deep intracranial bleed without neurological deficit while on warfarin which was managed successfully.

Transoesophageal echocardiography (TOE) was done initially on all four selected patients to exclude LA & LAA clots and to measure LAA diameters. Diameters taken were of the LAA orifice and the neck, 10 mm perpendicularly down and parallel to orifice (Figure 1). TOE was also done during the procedure and dimensions measured to confirm and to decide the size of the occluder. In all four patients right femoral venous access was obtained with a 12F sheath. A 0.032-inch guidewire was advanced to left subclavian vein. The sheath was exchanged with an 8F Mullins Sheath. The System was withdrawn to right atrium and inter atrial septum (IAS) was punctured more inferiorly with a Brockenbrough needle under TOE and fluoroscopic guidance. A 5F Pig tail catheter was advanced through the sheath into the LAA and demarcated with a contrast injection (Figure 2)



Case Report

The pigtail catheter was removed and a Judkins Right (JR) catheter was introduced into left superior pulmonary vein (LSPV) over an extra stiff guidewire. The Mullins sheath was removed with the wire left in LSPV. The Amplatzer Amulet LAA occluder (22, 28, 25 & 25 mm devices respectively) was introduced over the wire. The System was withdrawn to the LAA orifice with the lobe of the device slightly deployed. The device was deployed after confirming the position with TOE and fluoroscopy (Figure 3). Post-deployment contrast injection did not show any peri-device leak (Figure 4).

After 6 months, all four patients were reviewed in the Cardiology follow up clinic and found to have no new complaints, history of any embolic events, palpitations and all were haemodynamically stable with rate-controlled AF.

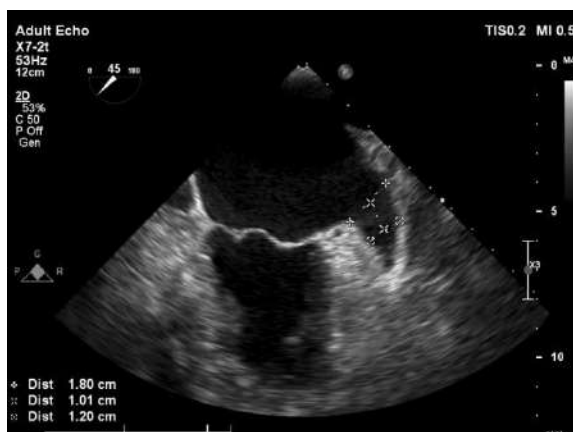


Figure 1: TOE image of LAA at 45° and diameters of the orifice and neck of LAA

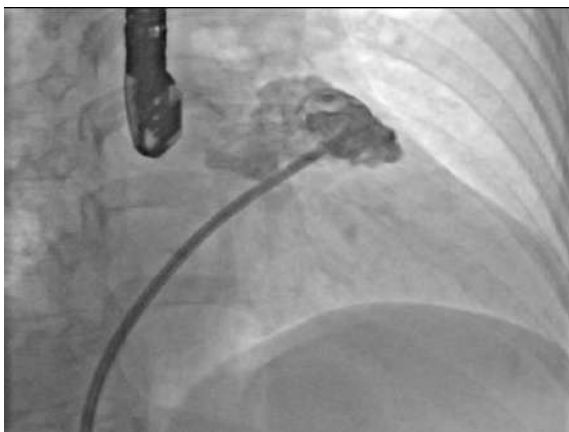

Figure 2: Angiographic image of LAA

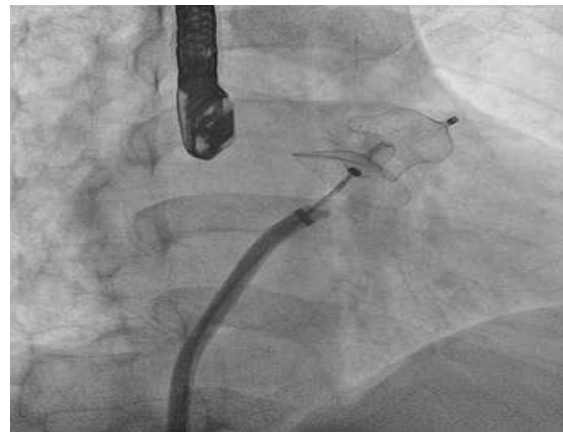

Figure 3: Deployment of the Amplatzer Amulet LAA occluder.

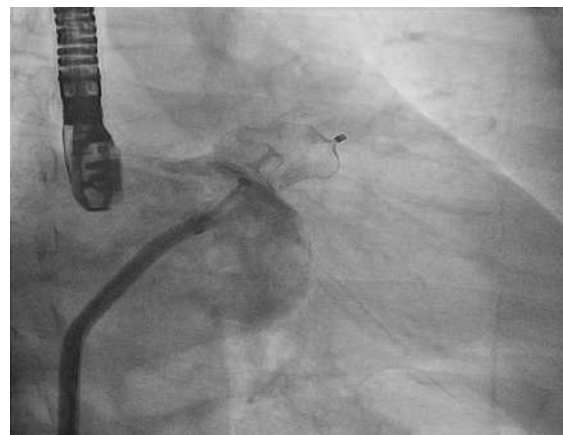


Figure 4: Post procedure LA angiography shows no leak of contrast into LAA.

Discussion

OAC use for stroke prevention in patients with AF has various disadvantages and complications including serious haemorrhages leading to death. Most commonly used OAC in Sri Lanka is warfarin which needs regular INR monitoring, strict compliance and has various interactions with food and drugs.

In patients who are unable to take OAC, other non-pharmacological approaches such as radiofrequency ablation does not seem to reduce embolic risk. Since the LAA is the common source of thrombi in AF (90%), percutaneous device closure or surgical exclusion is non-inferior to OAC for stroke prevention in AF patients with moderate stroke risk ^(3,4,10).



However 10% of the emboli are not from the LAA, and hence LAA device closure will not completely prevent stroke in AF patients ⁽²⁾. The European society of cardiology (ESC) recommends LAA percutaneous device occlusion for non-valvular AF patients with stroke risk and clear contraindications for OAC ⁽⁷⁾.

Amplatzer Amulet LAA occluder is the second generation Amplatzer LAA device made on proven Amplatzer technology and has significant advantages, including wider lobe and more stabilizing wires (up to 10 pairs) for improved device stability, and larger lobe size to occlude larger appendages⁽⁵⁾. This is the second commonest device to be used in LAA device closure worldwide after Watchman LAA device.

Conclusion

Major cause of ischaemic stroke in patients with AF is cardiac emboli arising from LAA. Long term anticoagulation is recommended in patients with AF and high stroke risk ⁽⁷⁾. Patients who are unable to take or having contraindications to taking OAC, LAA appendage occlusion with device is an option to prevent stroke ⁽⁷⁾.

Carrying out similar procedures regularly in the near future is being planned now and it will be available soon as a procedure of choice for patients having problems with OAC.

References

1. Stöhlberger C, Schneider B, Finsterer J. Elimination of the left atrial appendage to prevent stroke or embolism? Anatomic, physiologic, and pathophysiological considerations. *Chest*, 2003; 124(6): 2356-2362. doi:10.1378/chest.124.6.2356.
2. Blackshear JL, Odell JA. Appendage obliteration to reduce stroke in cardiac surgical patients with atrial fibrillation. *Ann Thorac Surg*, 1996; 61: 755.
3. Reddy VY, Sievert H, Halperin J, et al. Percutaneous Left Atrial Appendage Closure vs Warfarin for Atrial Fibrillation: A Randomized Clinical Trial. *JAMA*, 2014; 312(19): 1988–1998. doi: 10.1001/jama.2014.15192
4. Holmes DR Jr, Doshi SK, Kar S, et al. Left Atrial Appendage Closure as an Alternative to Warfarin for Stroke Prevention in Atrial Fibrillation: A Patient- Level Meta-Analysis. *J Am Coll Cardiol*, 2015; 65(24): 2614-2623. doi: 10.1016/j.jacc. 2015. 04.025
5. Meier B, Palacios I, Windecker S, et al. Transcatheter left atrial appendage occlusion with Amplatzer devices to obviate anticoagulation in patients with atrial fibrillation. *Catheter Cardiovasc Interv* 2003; 60: 417.
6. Landmesser U, Schmidt B, Nielsen-Kudsk JE, et al. Left atrial appendage occlusion with the AMPLATZER Amulet device: periprocedural and early clinical/ echocardiographic data from a global prospective observational study. *EuroIntervention* 2017; 13: 867.
7. Paulus Kirchhof, Stefano Benussi, Dipak Kotecha, Anders Ahlsson, Dan Atar, Barbara Casadei, Manuel Castella, Hans-Christoph Diener, Hein Heidbuchel, Jeroen Hendriks, Gerhard Hindricks, Antonis S Manolis, Jonas Oldgren, Bogdan Alexandru Popescu, Ulrich Schotten, Bart Van Putte, Panagiotis Vardas, ESC Scientific Document Group, 2016 ESC Guidelines for the management of atrial fibrillation developed in collaboration with EACTS, *European Heart Journal*, 7 October 2016; 37(Issue 38): 2893-2962. <https://doi.org/10.1093/eurheartj/ehw210>
8. Sievert H, Lesh MD, Trepels T, et al. Percutaneous left atrial appendage transcatheter occlusion to prevent stroke in high-risk patients with atrial fibrillation: early clinical experience. *Circulation*, 2002; 105: 1887.
9. Ostermayer SH, Reisman M, Kramer PH, et al. Percutaneous left atrial appendage transcatheter occlusion (PLAATO system) to prevent stroke in high-risk patients with non-rheumatic atrial fibrillation: results from the international multi-center feasibility trials. *J Am Coll Cardiol*, 2005; 46: 9.
10. Holmes DR, Reddy VY, Turi ZG, et al. Percutaneous closure of the left atrial appendage versus warfarin therapy for prevention of stroke in patients with atrial fibrillation: a randomised non-inferiority trial. *Lancet*, 2009; 374: 534.



Case Report

Acute Anterior ST Elevation Myocardial Infarction complicated with Ventricular tachycardia due to Diffuse Coronary Artery Spasms

Wickramarachchi CP¹, Senanayake S¹, Lokuketagoda K¹, Herath J¹, Amarasena N¹, Kottegoda S¹

1. Sri Jayewardenepura General Hospital, Sri Lanka.

Corresponding Author: Dr. C P Wickramarachchi

E-mail: chintaka1985@gmail.com

Abstract

Myocardial infarction with non-obstructive coronary arteries (MINOCA) is the terminology currently used to describe patients presenting with clinical symptoms of myocardial infarction without fixed obstructions in epicardial coronary arteries. Epicardial and micro vascular coronary artery spasms are known causes in above category. Vascular endothelial dysfunction also contributes to the above clinical entity. Coronary artery spasm is a functional disorder, which is caused by intense, reversible obstruction of coronary arteries. We report a case of a patient presenting with acute anterior STEMI complicated with ventricular tachycardia requiring cardioversion to the emergency department. His coronary angiogram showed diffuse stenotic segments in both left anterior descending and circumflex arteries. Those coronary artery obstructions were improved with intra coronary administration of GTN. Thus we objectively diagnosed epicardial coronary artery spasms and commenced treatment with calcium channel blockers, oral nitrates, statin and ACE inhibitor.

Keywords: Diffuse coronary spasm, VT, STEMI

Case report

A 64-year-old male patient with diabetes mellitus and hypertension presented to our emergency department with constricting type of chest pain radiating to his back. He had nausea and sweating too. The patient's conscious level suddenly deteriorated and he collapsed. Patient was attached to a cardiac monitor and was found to have fast ventricular tachycardia which evolved in to ventricular fibrillation (Figure 1) with haemodynamic instability. Patient was resuscitated with DC cardioversion. His ECG reverted back to sinus rhythm with ST segments elevations were noted in V2 to V6 leads (Figure 2).

The patient was treated with loading doses of dual antiplatelet agents (aspirin 300 mg and clopidogrel 600 mg PO), morphine sulphate 3 mg IV bolus and 5000 IU bolus of intravenous heparin. An urgent 2D echocardiogram was performed and it showed ejection fraction of 55% with anterior and apical wall hypokinesia. Coronary angiography (CAG) was performed immediately. However, no critical lesions were found. However, there was a 60% discrete narrowing noted in mid circumflex artery (Figure 2). In addition, another minor narrowing was noted in proximal left anterior descending artery. 100 micrograms of intra coronary nitroglycerin (GTN) was administered and repeat cineangiogram was performed. It showed normalization of coronary arteries with no residual stenosis (Figure 4). This was highly suggestive of resolution of coronary artery spasms. Troponin-I level of the patient was found to be 12.5 ng/L (0–0.028). His full blood count was within normal limits apart from neutrophil leukocytosis.

Since the CRP was normal we postulated that transient myocardial ischaemia caused the elevated WBC counts. His electrolytes including Na, K and Mg were within normal limits. His 24 hour holter monitoring did not reveal much abnormalities apart from few RVOT extra systoles. His cardiac MRI did not reveal significant abnormalities such as scarred myocardium or left ventricular hypertrophy. Thus the patient was diagnosed as vasospastic myocardial infarction (MI) and discharged 2 days later with calcium channel blockers (Diltiazem 30 mg bd) and oral nitrates. Patient was registered at cardiology outpatient clinic for close follow up.

Discussion

Vasospastic angina is an important functional cardiac disorder that leads to transient myocardial ischemia and is caused by sudden, intense and reversible coronary artery spasm resulting in subtotal or total occlusion. Coronary vasospasms may be focal or diffuse, and it can involve a single or multiple epicardial coronary arteries. This condition can present with spectrum of clinical scenarios such as stable angina, acute coronary syndromes and lethal arrhythmias. Vasospasm is predominantly caused by hyper-reactive vascular smooth muscle cells and probably endothelial dysfunction which is not fully understood. Prevalence of vasospastic angina has been reported as low as less than 1% of hospital admissions. Optimum administration of calcium channel blockers is a promising therapeutic option in preventing vasospastic angina and myocardial infarctions.

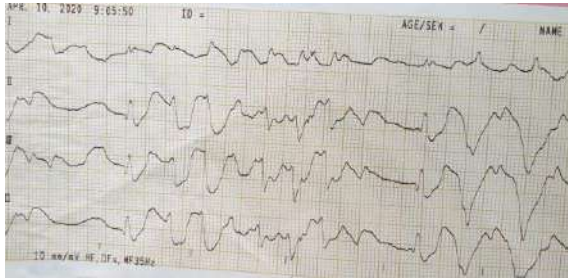


Figure 1: ECG: Ventricular tachycardia degenerates in to ventricular fibrillation.

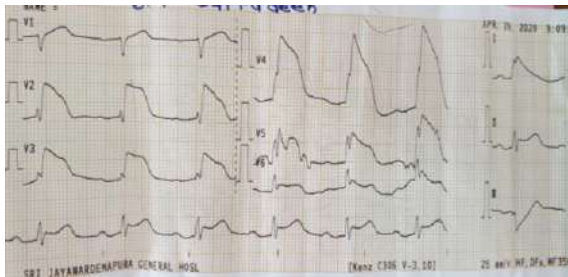


Figure 2: ST segment elevations in anterior precordial leads

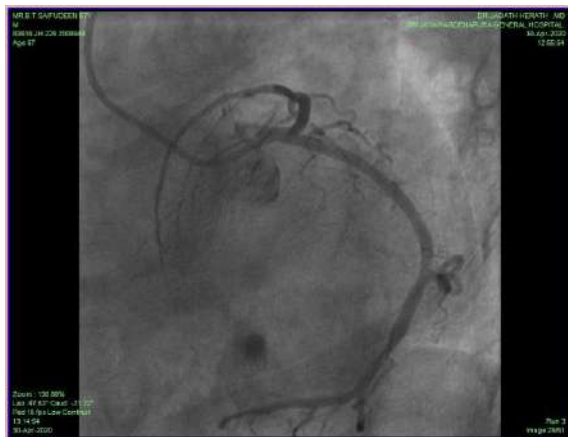


Figure 3: Significant narrowing at distal circumflex artery.

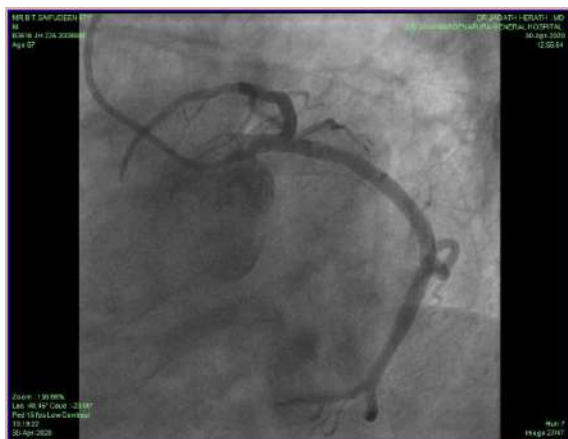

Figure 4: Resolution of coronary artery spasms

Studies have shown that combination therapy of statins with ACE inhibitors have beneficial effect on vascular endothelial dysfunction, which also aggravate coronary artery spasms.

References

1. Takagi Y, Takahashi J, Yasuda S, Miyata S, Tsunoda R, Ogata Y, et al. Prognostic stratification of patients with vasospastic angina: a comprehensive clinical risk score developed by the Japanese Coronary Spasm Association. *J Am Coll Cardiol.* 2013;62(13):1144–53. [PubMed]
2. Crea F, Lanza GA. New light on a forgotten disease: vasospastic angina. *J Am Coll Cardiol.* 2011;58(12):1238–40.
3. Kim MC, Ahn Y, Park KH, Sim DS, Yoon NS, Yoon HJ, et al. Clinical outcomes of low-dose aspirin administration in patients with variant angina pectoris. *Int J Cardiol.* 2013;167(5):2333–4.
4. Lanza GA, Careri G, Crea F. Mechanisms of coronary artery spasm. *Circulation.* 2011;124(16):1774–82.
5. The Task Force on the management of stable coronary artery disease of the European Society of Cardiology. 2013 ESC guidelines on the management of stable coronary artery disease—addenda. *Eur Heart J.* 2013;34(38):2949–30.
6. Lanza GA, Sestito A, Sgueglia GA, Infusino F, Manolfi M, Crea F, et al. Current clinical features, diagnostic assessment and prognostic determinants of patients with variant angina. *Int J Cardiol.* 2007;118(1):41–7. [PubMed] [Google Scholar]
7. Lanza GA, Crea F. Pathophysiology and assessment of coronary spasm. In: Escaned J, Serruys PW, editors. *Coronary Stenosis: Imaging, Structure and Physiology.* New York, NY: Europa Editions; 2010. pp. 415–430.
8. Takagi Y, Yasuda S, Tsunoda R, Ogata Y, Seki A, Sumiyoshi T, et al. Clinical characteristics and long-term prognosis of vasospastic angina patients who survived out-of-hospital cardiac arrest: multicenter registry study of the Japanese Coronary Spasm Association. *Circ Arrhythm Electrophysiol.* 2011;4(3):295–302.



Case Report

Distortion and Fracture of the proximal portion of a stent in the left main coronary artery that was successfully managed with a conservative approach

Boralessa MDS¹, Sampath Withanawasam¹

1. Cardiology Unit, National Hospital Sri Lanka (NHSL), Colombo, Sri Lanka.

Corresponding author: Dr. M D S Boralessa

E-mail: mahenbora1984@gmail.com

Abstract

Coronary stent distortion and fracture are rare and unfortunate events. It is associated with potential complications that include acute coronary syndrome, stent thrombosis or in-stent restenosis that may require repeat revascularization of target vessels or even sudden cardiac death. We present the case of a 61-year-old lady with a strong family history of ischemic heart disease (IHD), who was evaluated for recent onset deteriorating exercise capacity. She underwent coronary angiography after preliminary investigations. The angiography revealed severe atherosclerotic disease of her left main coronary artery (LMCA) extending into the left anterior descending artery (LAD). The patient having refused cardiac bypass graft surgery (CABG) opted to proceed with percutaneous coronary intervention (PCI) requiring stenting from the LMCA to LAD. Her PCI procedure was complicated with the development of stent distortion followed by fracture of the proximal part of the LMCA stent. Procedure was stopped after kissing balloon dilatation and Proximal Optimization Technique (POT) without implanting further stents. She remained clinically stable throughout the procedure and was asymptomatic. She received close follow up and underwent a repeat check coronary angiography after 6 months that revealed good angiography results with absence of in-stent restenosis or evidence of residual stent fracture. The patient clinically improved and remained asymptomatic following PCI.

Key words: Left main coronary artery (LMCA), percutaneous coronary intervention (PCI), stent fracture

Case report

A 61-year-old previously healthy lady was investigated following a complaint of worsening exercise tolerance since 1 month. She had a strong family history of IHD and both of her siblings had undergone PCI. There was no parental history of IHD and both siblings were above the age of 50 at the time of undergoing PCI. Her investigations revealed lipid profile within normal range and there was good glycemic control. Her electrocardiogram (ECG) did not reveal any ischemic changes and was in sinus rhythm. Her echocardiogram was normal. Due to associated strong family history of IHD, she underwent further investigation with coronary angiography that revealed severe atherosclerotic disease of the LMCA extending into the LAD (Figure 1). She received initial counselling to undergo CABG but opted for PCI after refusal of CABG.

The PCI procedure was done with right side femoral approach. A 7 Fr Judkins left (JL) catheter was used to engage the left coronary system. Catheter engagement and alignment was not optimal throughout the procedure.

A SION BLUE guide wire was used to cross the LMCA to LAD lesions whilst a RINATO guide wire was used to secure the left circumflex artery (LCX). A 2.5 x 8mm NC HAWK balloon was used to pre-dilate the LMCA to LAD lesions at pressure of 6 to 8 atm. The LMCA to LAD was stented with XIENCE EXPEDITION 3.0 x 38mm drug eluting stent (DES), which was deployed at 10atm, covering the ostium with minimum protrusion into the aorta.

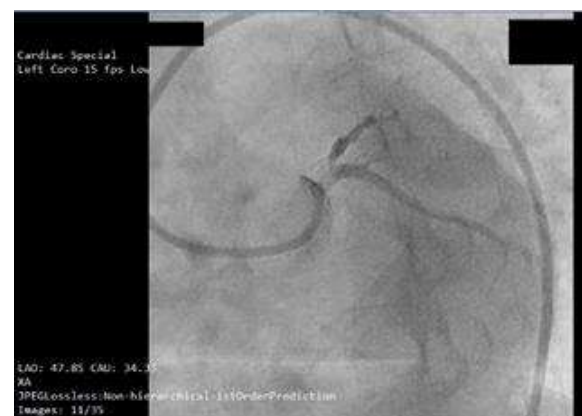

Figure 1:



The LMCA stent was post-dilated (POT) with NC TREK 4.0 x 8 mm balloon at 18 - 24 atm. The stent in the LAD was post-dilated with a 3.0 x 8.0 HAWK NC balloon at 16 - 24 atm and kept in LAD for KBD. The LCx was rewired with the existing RINATO guide wire to accomplish KBD. 2.5 x 12 LACROSSE NC balloon was unable to pass to LCx due to resistance at mid LMCA. At this point, Stent visualization with stent boost revealed severe distortion and fracture of the proximal part of the LMCA stent, most likely caused by attempted balloon advancement on the LCX guidewire which traverse between the wall of the LMCA and stent struts.

LMCA stent was re-dilated with 3.0 x 8.0 NC balloon which was kept in LAD and then repeated POT with 4.0x8.0 NC balloon. The LCX was rewired and crossed with 1.5 x 8.0 SC and 2.5 x 8.0 NC balloons sequentially. Kissing balloon dilatation was performed with a LACROSSE NC 2.5 x 10 mm balloon was placed in the LAD and HAWK NC 2.5 x 8 mm balloon in the LCX, whilst both balloons were inflated at 10 atm. A final POT was done with MOZEC NC 4.0 x 8mm balloon inflated at 20 atm. Stent Boost revealed stent fracture with V shape gap of the proximal portion of the LMCA stent (Figure 2).

The patient remained clinically stable throughout procedure. Despite the noted fracture, there was TIMI III flow in the left system without evidence of complications such as coronary dissection, perforation or thrombus formation (Figure 3).

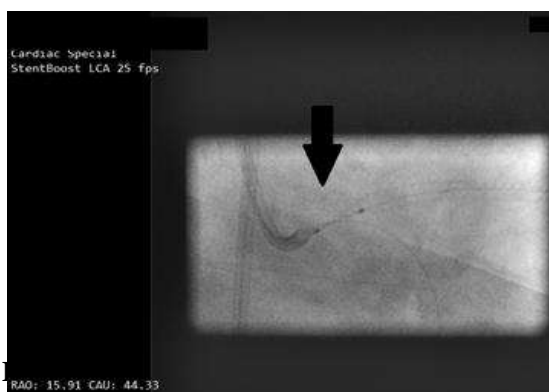


Figure 2

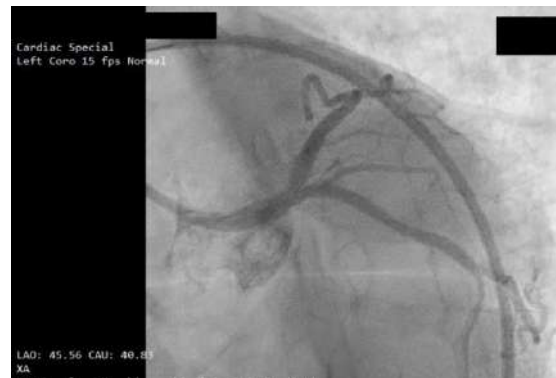

Figure 3:

Thereafter, the next available options were considered,

1. Deployment of an additional stent on the proximal LMCA in order to superimpose the fracture segment of the existing stent.
2. Conservative management – Observe and intervene if the patient develops symptoms or hemodynamic instability, in order to reduce metal load that may occur with an additional stent.

Since the patient was asymptomatic and haemodynamically stable, a conservative approach was decided. The patient's recovery period was uneventful and she was discharged from the hospital 03 days after the procedure on ticagrelor 90 mg/bd and aspirin 75 mg/ nocte alone with other routine medicines. She underwent close follow up. She was noted to have improved exercise capacity following PCI. She underwent a repeat check angiography 6 months later that revealed good angiography results and absence of in-stent restenosis (Figure 4). Unfortunately, further detailed imaging of the stent structure by intravascular ultrasound (IVUS) or optical coherence topography (OCT) could not be performed on this patient during both times of angiography due to limited resources and facilities available.

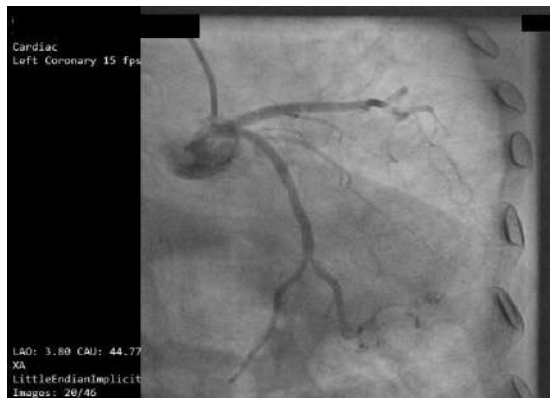

Figure 4:

Discussion

Stent distortion (SD) is a rare event that can occur even after successful deployment of a stent. It may occur following several reasons due to mechanical insults such as balloon dilatation over a guidewire that traverses outside the stent lumen, entrapment of guidewires, balloons or other devices and balloon inflation of side branches through the stent struts ⁽¹⁾. There are only few studies published regarding stent distortion and awareness of the problem has only recently emerged. Therefore further studies are required to assess the magnitude and impact associated with SD.

Stent fracture (SF) is defined as the loss of continuity of the stent struts, as detected by imaging modalities such as fluoroscopy, IVUS or OCT ⁽²⁾. The detection of SF is important since it may potentially cause stent thrombosis or restenosis, which in turn may lead to acute coronary syndrome ⁽³⁾. The incidence of stent fracture (SF) ranges between 1 to 8% ⁽⁴⁾.

However, the incidence of SF may be underestimated since it may be difficult to detect SF with use of conventional angiography solely. Several SF classification schemes have been proposed based on the morphology of SF. However a consensus is required for an accepted universal classification.

A classification proposed by Nakazawa, *et al* ⁽⁵⁾, classified SF into the following categories:

- Grade I – Single strut fracture
- Grade II – 2 or more struts fractured
- Grade III – 2 or more struts fractured with deformity
- Grade IV – Complete transection of stent but without a gap
- Grade V – Complete transection causing a gap in the stent

Among the many factors that predispose to development of stent fracture,

1. Over expansion of the stent that may cause weakening of stent struts ⁽⁶⁾
2. Use of long length stents, that may undergo higher radial force ⁽⁶⁾
3. Overlapping of stents, that may cause rigidity and create hinge points that can deform the stent and lead to fracture ⁽⁷⁾
4. Errors during handling of the stent ⁽⁸⁾
5. Type of stenting technique e.g.; Crush technique ⁽⁹⁾
6. Anatomical factors such as angulated vessels, tortuosity, long lesions, etc. ⁽¹⁰⁾.

The management of SF is dependent on many factors such as the morphology of the fracture, the presence of cardiac ischemia and the presence of the above listed predisposing factors of SF. However, further studies are required to publish a consensus on the accepted management of SF. The options of management include conservative management, restenting or surgical management ⁽¹¹⁾.

Our patient's PCI was complicated due to the following reasons,

1. Poor guide catheter engagement that provided poor support during the procedure and caused technical difficulties during rewiring of the LCX and passage of balloons.



2. The suspected passage of the guide wire outside of the lumen of the stent in the LMCA into the LCX, most likely caused by inadequate deployment of the LMCA stent due to lack of imaging modalities such as IVUS and OCT to assess adequate stent deployment.
3. Distortion of the stent during attempted passage against resistance of the balloon into the LCX on the guide wire.
4. Stent fracture caused by balloon passage through the struts and dilatation of a distorted stent at high pressures.

Despite the above complications the patient remained stable during procedure and underwent conservative management. The patient made an uneventful recovery, she experienced improvement of her symptoms and a repeat check angiography demonstrated good results.

Conclusion

This case highlights the importance of the need of imaging modalities such as IVUS or OCT during PCI to optimize stent deployment and adequate apposition. This would prevent complications such as inadvertent passage of guidewires and devices outside of the stent lumen and prevent consequences on the structure of the stent. Therefore a high level of vigilance is required if resistance is encountered during rewiring and delivery of devices after deployment of a stent. Adequate engagement of guide catheters are essential, especially during high risk PCI such as LMCA stenting in order to reduce technical difficulties that may be encountered during rewiring and delivery of devices.

This case highlights that conservative management without re-implanting a second stent even at high risk sites like LMCA is beneficial in selected patients despite presence of stent fracture. Second stent implantation leaves excess metal load in the vessel and is not hazard free.

References

1. Hernandez RA, Surez A. Diagnosis and treatment of coronary stent entanglement complicated by extreme stent distortion. *JIC*, 3 March 2008; 30.
2. Lee SE, Jeong MH, Kim IS, Ko JS, Lee MG, Kang WY, et al. Clinical outcomes and optimal treatment for stent fracture after drug-eluting stent implantation. *J Cardiol*, 2009; 53: 422-428.
3. Shaikh F, Maddikunta R, Djelmami-Hani M, Solis J, Allaqaband S, Bajwa T. Stent fracture, an incidental finding or a significant marker of clinical in-stent restenosis? *Catheter Cardiovasc Interv*, 2008; 71: 614-618.
4. Alexopoulos D, Xanthopoulou I. Coronary Stent Fracture: How Frequent It Is? Does It Matter?. *Hellenic J Cardiol*, 2011; 52: 1-5.
5. Nakazawa G, et al. Incidence and predictors of drug-eluting stent fracture in human coronary artery a pathologic analysis. *J Am Coll Cardiol*, 2009 Nov 17; 54(21): 1924-1933.
6. Chhatrwalla AK, Unzek S, Kapadia SR. Recurrent Stent Fracture in the Right Coronary Artery. *Clin Cardiol*, 2010; 33: E70-2.
7. Leong DP, Dundon BK, Puri R, Yeend RA. Very late stent fracture associated with a sirolimus-eluting stent. *Heart Lung Circ*, 2008; 17: 426-428.
8. Ramegowda RT, Chikkaswamy SB, Bharatha A, Radhakrishna J, Krishnanai GM, Nanjappa MC, et al. Circumferential Stent Fracture. Novel detection and treatment with the use of stent boost. *Tex Heart Inst J*, 2012; 39: 431-434.
9. Surmely JF, Kinoshita Y, Dash D, Matsubara T, Terashima M, Ehara M, et al. Stent strut Fracture – Induced restenosis in a bifurcation lesion treated with the crush stenting technique. *Circ J*, 2006; 70: 936-938.
10. Canan T, Lee MS. Drug-eluting stent fracture: Incidence, contributing factors, and clinical implications. *Catheter Cardiovasc Interv*, 2010; 75: 237-245.
11. Park KW, Park JJ, Chae IH, Seo JB, Yang HM, Lee HY, et al. Clinical Characteristics of Coronary Drug-Eluting Stent Fracture: Insights from a Two-Center DES Registry. *J Korean Med Sci*, 2011; 26: 53-58.



Case Report

Left anterior descending artery(LAD) lesion presenting as acute inferior ST elevation myocardial infarction(STEMI)

De Vas Goonewardane, APN ¹; De Silva GID ²; Herath JH ²; Kottegoda, SR ²

1. Royal Brompton and Harefield NHS trust, UK.

2. Sri Jayawardenepura general hospital, Colombo, Sri Lanka.

Corresponding author: Dr De Vas Goonewardane.

E-mail: n.vasgoonewardane@rbht.nhs.uk

Abstract

Inferior ST Elevation instead of reciprocal ST depression, along with a culprit LAD lesion is a rare combination. It is an important association because of increased morbidity and mortality. 69-year-old patient presented with subtle inferior ST elevation and ongoing ischaemia. Catheterization revealed a culprit distal LAD lesion with a 90% plaque and high thrombus burden. Angioplasty and stenting of the LAD restored TIMI 3 flow with pain resolution but failed to demonstrate a wrap-around path in RAO projection. Later he developed V2-V5 ST elevation with symmetrical T wave inversion and concomitant worsening of inferior STE but was devoid of new onset angina. Patient made an uneventful recovery to be discharged on day 5 of admission. Distal LAD occlusion, wrap-around LAD path and previously ischaemic inferior territory with heavy collateral supply has been independently associated with concomitant inferior STE during culprit LAD lesion. Careful scrutiny of angiogram and appropriate treatment is mandatory to improve acute and long term outcomes.

Keywords: LAD lesion, Inferior STEMI

Introduction

Inferior ST elevation instead of reciprocal ST depression, along with a culprit LAD lesion is a rare combination. This entity is important to identify early because these patients have poor outcomes with regards to morbidity and mortality ^(1,2). In most occasions the presentation is due to a “wrap around apex” LAD which is one of the four types of LAD distributions. But we present a case of similar presentation without the so called “wrap-around apex” path of LAD.

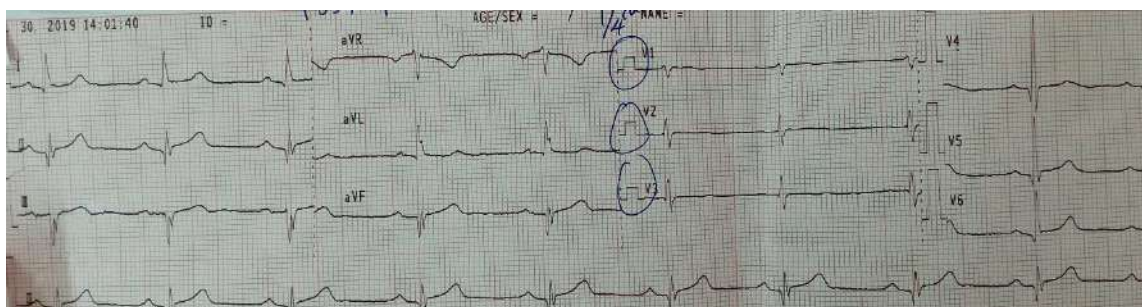
Case Report

69-year-old patient with diabetes mellitus presented with acute ischaemic pain for two hours duration. First EKG on admission revealed subtle inferior ST elevation along with antero-septal T wave flattening. The findings were supported by portable 2D Echo assessment showing inferior, inferoseptal, antero-septal hypokinesia with a LVEF of 50%. Patient was taken immediately to the cardiac catheterisation laboratory after initial antiplatelet loading. Despite the ongoing ischaemic pain his haemodynamic parameters were stable with 130/70mmHg blood pressure and a heart rate of 90/minute in sinus rhythm.

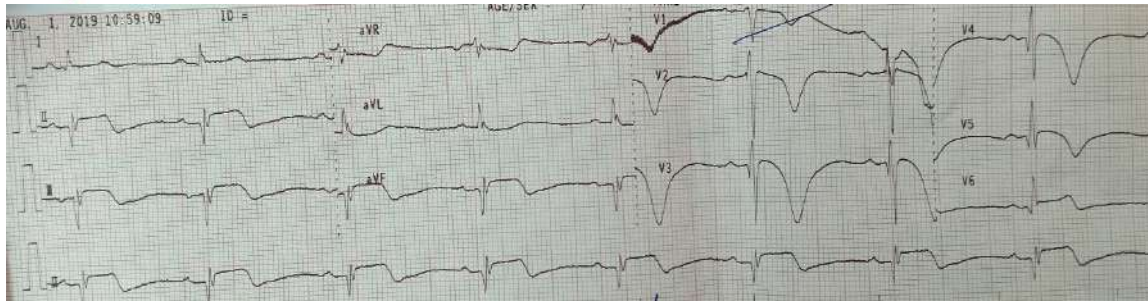
To our surprise culprit artery was found to be the LAD with a 90% ulcerated plaque in mid-distal vessel with high thrombus burden and distal TIMI 2 flow.

Right coronary (RCA) was dominant with minor plaque involvement although the distal PLV and PDA branches were small in calibre and diffusely diseased. We proceeded with balloon angioplasty and stenting of the LAD with a drug eluting stent and intracoronary 2b/3A administration restoring the TIMI 3 flow and alleviating the ischaemia. Afterwards it was noticed that distal LAD was not a wrap-a-round vessel which supplies a significant area of the inferior myocardium in the right oblique projection.

During post PCI stay in high dependency unit he developed V2-V6 ST elevation followed by deep symmetrical T wave inversions the following day which is known to be a good prognostic sign in terms of LAD revascularization⁽⁶⁾.



A) ECG on admission prior to revascularization.



B) ECG on Day 1 post Revascularization.

Baseline investigations revealed haemoglobin of 13.2g/dl, Platelet of 188000/ul, Troponin I titre of 37.16 ng/ml and serum creatinine of 104 umol/l. Repeat ECHO assessment showed resolution of previously noted antero-septal hypokinesia and patient made an uneventful recovery to be discharged on day 5 of admission. ECHO assessment showed resolution of septal hypokinesia but persistent mild inferior segmental defects.

Discussion

The inferior lead (ii, iii, aVF) ST elevation is traditionally associated with either a RCA or a dominant circumflex lesion. Very rarely one can encounter a wrap-a-round LAD which supplies at least one fourth of inferior segments in right oblique projections of the heart⁽³⁾. It was unique in this case that initially inferior changes were not associated with prominent anterior EKG changes though the lesion was in mid to distal LAD. In addition, our patient did have a mid-distal LAD occlusion without being wrap-around which is rarer⁽¹⁾. On the other hand, distal LAD lesions may cause inferior STE without inferior wall involvement due to the injury vector being directed left and downwards. Attenuation of the usually expected reciprocal ST depression in inferior ECG leads is also an indirect clue to dominant LAD supply in some patients⁽⁴⁾. Features put forward in previous studies for concomitant/isolated inferior STE in LAD occlusion are⁽⁵⁾,

1. The site of LAD artery occlusion (distal occlusion).
2. LAD artery extension on the inferior wall of left ventricle (wrap-around LAD)
3. Collateral flow from the LAD artery to the inferior wall.

The LAD artery holds added importance in all of these patients and careful scrutiny of the angiogram is necessary to pick the culprit lesion.

Ischemic myocardium subtended by the infarct-related artery may not exhibit a uniform degree of ischemia due to a heterogenous collateral network.

In addition, the heart's spatial placement in thorax, Wilson's central terminal placement, the presence of previously silent-infarcted areas, asymmetric distribution of the myocardial mass, or timing of the ischemic process may all influence the magnitude and the direction of the ischemic vector.

In our patient the explanation could be a combination of above factors as well as unidentified distal collaterals from LAD to inferior segments which were clogged with thrombi during the initial angiogram. Myocardial perfusion imaging would be an objective way of assessing ischaemic territory in these patients once stable.

References

1. Bozbeyoglu E, Yildirimturk O, Aslanger E, Simsek B, Karabay CY, Ozveren O, et al. Is the inferior ST-segment elevation in anterior myocardial infarction reliable in prediction of wrap-around left anterior descending artery occlusion? *Anatol J Cardiol* 2019; 21: 253-8.
2. Kobayashi N, Maehara A, Mintz GS, Wolff SD, G  n  reux P, Xu K, et al. Usefulness of the Left Anterior Descending Artery Wrapping Around the Left Ventricular Apex to Predict Adverse Clinical Outcomes in Patients With Anterior Wall ST-Segment Elevation Myocardial Infarction (an INFUSE-AMI Substudy). *Am J Cardiol* 2015; 115: 1389-95.
3. Sunil Roy TN, Nagham JS, Kumar RA. Acute inferior wall myocardial infarction due to occlusion of the wrapped left anterior descending coronary artery. *Case Reports in Cardiology*. 2013. Article ID: 983943, 3 pages. <http://dx.doi.org/10.1155/2013/983943>.
4. Lew AS, Hod H, Cercek B, Shah PK, Ganz W. Inferior ST segment changes during acute anterior myocardial infarction: a marker of the presence or absence of concomitant inferior wall ischemia. *J Am Coll Cardiol* 1987; 10: 519-26.
5. Hossein S, Kheirieh A, Azmoodeh E. Inferior ST-Segment Elevation Caused by Occlusion of Left Anterior Descending Artery. *Journal of Medicine and Life* Vol. 13, Issue 1, January-March 2020, pp. 98–101
6. Lee MJ, Jang JH et al. Prognostic Implications of Newly Developed T-Wave Inversion after Primary Percutaneous Coronary Intervention in Patients with ST-Segment Elevation Myocardial Infarction. *Am J Cardiol*. 2017;119 (4):515-519.



Case Report

Retrieval of a stalled rotablator burr using a modified double guide-guideliner technique

Kabir T¹, Panoulas V¹, De Vas Goonewardane APN¹

¹ Royal Brompton and Harefield NHS trust, UK.

Corresponding author: Dr De Vas Goonawardana.

E-mail: n.vasgoonewardane@rbht.nhs.uk

Abstract

Lesion modification through Rotablation is well-established and extensively practiced worldwide. It demands certain amount of technical expertise to master. Out of the possible complications stalled burr is a dreaded and life-threatening complication. An 83-year-old male was referred on emergency basis with a stalled rotablation burr in LAD (Left anterior descending). He was ischaemic and maintaining a marginal blood pressure on an intra-aortic balloon pump and fluids. Surgical options were limited and decision was made to attempt a high-risk retrieval. 8Fr Parallel guide was placed via the left femoral artery. Multiple parallel wires used to cross the burr position were in vain. Limited small balloon inflations were performed in the region of interest. 7 French Guideliner over the cut rota burr was not successful either. Burr was finally retrieved using NC balloon to trap Rota stem within the Guideliner at high pressures. Procedure was completed with implantation of two stents to LAD after further rotablation. IVUS (Intra-vascular ultrasound) run confirmed satisfactory results. Most complications of Rotablation is due to technical deficiencies. It is very important to get extensively trained under an experienced operator in terms of the technique and bailout strategies during complications. Every situation is unique and demands a custom-tailored approach. Here we propose a technique of retrieval, combining double wire and guide liner techniques.

Keywords: Rotablation, IVUS, LAD, stalled burr, retrieval

Case Report

We report a case of an 83-year-old male undergoing angioplasty following admission with a troponin positive acute coronary event to a district general hospital. After initial diagnostic views through radial access it was planned to perform upfront rotablation in view of lesion modification. Unfortunately during this procedure the 1.5mm rotablation burr stalled and was not retrievable (Figure 1). After trying all the possibilities locally, the symptomatic patient was rushed to our center by paramedics with an intra-aortic balloon pump inserted from right femoral artery.

Immediate surgical opinion was sought and surgeons decided that it was not likely to yield a positive outcome unless as a bailout strategy.

First a parallel guide was placed via the left femoral artery using an 8 French sheath. An 8 French EBU 3.5 guide catheter was co-aligned. Heparin was administered keeping the ACT at a higher range between 300-350. Using a variety of parallel wires including Sion Black, Whisper and Fielder XT attempts to loosen up the plaque was carried out using a 1.0, 1.5 and 2.0 balloons. But it was not possible to negotiate any wire beyond the stalled burr.

An attempt was made to retrieve the 1.5mm rota burr with a 7 French guideliner over the cut rota burr (Figure 2) through radial guide which was not successful. During the procedure there was a transient cardiac arrest which responded to CPR and adrenaline injection.

Ultimately the burr was retrieved with gentle traction along with a 2.5x30-NC balloon trapping the burr stem within the guideliner and guide catheter at high pressure of 30ATM. This then enabled PCI to the LAD and left main stem to be undertaken sequentially using the left femoral guide system which was already in place.

Procedure was completed with implantation of two stents after further rotablation with TIMI 3 antegrade flow (Figure 3). IVUS (Intra-vascular ultrasound) run was carried out to exclude complications and confirm adequate stent expansion.

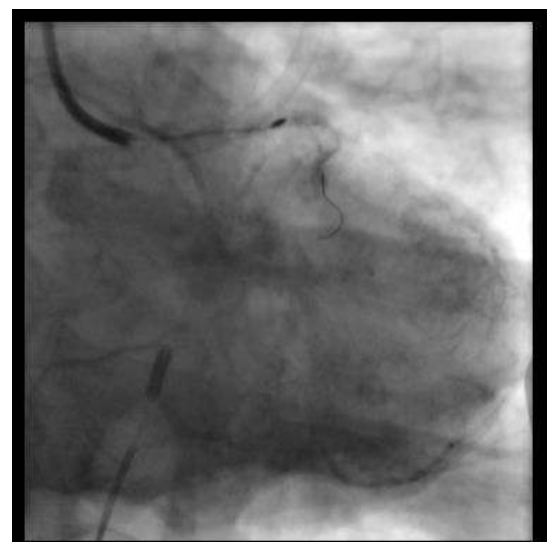

Figure1- Stalled LAD burr with intra-aortic balloon on background.

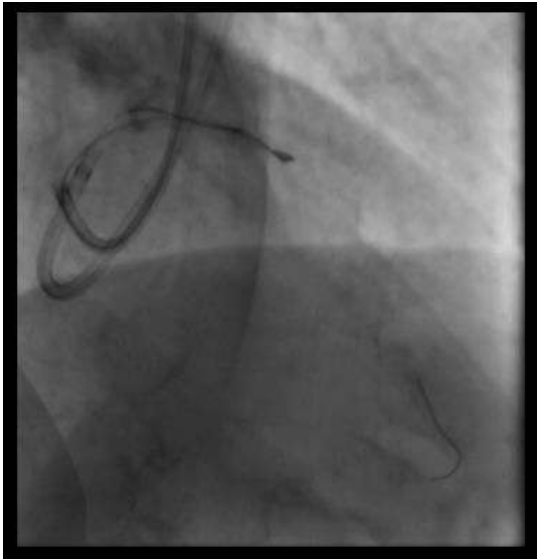


Figure 2- Parallel guide technique of wiring pass the burr.

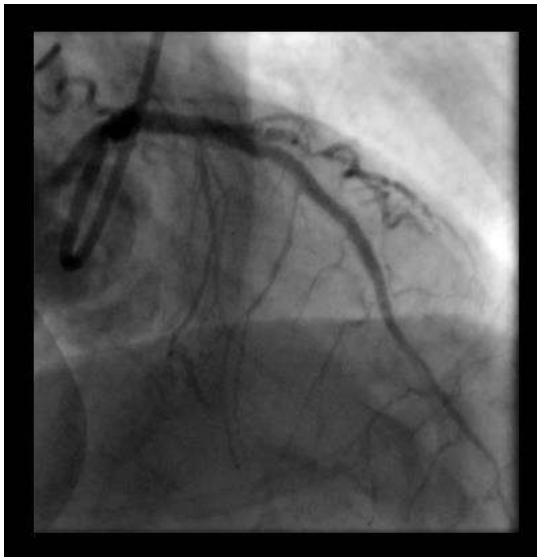


Figure 3- Final cineangiogram after stent placement.

We describe a modified technique by combining few of these techniques including disassembly of rotor driveshaft. We conclude that meticulous attention to the technique should be adhered to during rotablation at all times and that necessary hardware and human expertise to be in vicinity should a need arise for treating a rotablation complication.

References

1. Mechery A, Jordan PJ, Doshi SN, Khan SQ. Retrieval of a stuck Rotablator burr ("Kokeshi phenomenon") and successful percutaneous coronary intervention. *J Cardiol Cases*. 2015;13(3):90-92. Published 2015 Dec 10. doi:10.1016/j.jccase.2015.10.012
2. Chiang CH, Liu SC. Successful Retrieval of an Entrapped Rotablator Burr by Using a Guideline Guiding Catheter and a Snare. *Acta Cardiol Sin*. 2017;33(1):96-98. doi:10.6515/acs20160404a
3. Kimura M, Shiraishi J, Kohno Y. Successful retrieval of an entrapped Rotablator burr using 5 Fr guiding catheter. *Catheter Cardiovasc Interv*. 2011;78(4):558-564. doi:10.1002/ccd.22995

Discussion

This entrapment of a rota burr is a rare phenomenon, associated with significant anxiety and usually demanding for surgical measures. The Japanese have termed this the "Kokeshi phenomenon" named after a wooden doll found in northern Japan¹.

There are several bailout endovascular approaches that have been proposed, including simple manual traction, deep engagement, parallel guide wire and balloon inflation to loosen, using a snare for forceful local traction, or a child-in-mother catheter to facilitate the successful retrieval^{2,3}.



Case Report

A case of Peripheral Vascular Intervention for Chronic Total Occlusion of the Popliteal Artery

D.M. Liyanage¹, N. Fernando¹, T. Vaikunthan¹, L.S. Kularatne¹, T. Pereira¹

1. Institute of Cardiology, National Hospital of Sri Lanka.

Corresponding Author: Dr D M Liyanage.

E Mail: wow_dinuka@yahoo.com

Abstract

Peripheral arterial disease (PAD) consists of a spectrum from asymptomatic stenosis to limb-threatening ischemia. During the last decade a tremendous number in the variety of endovascular devices and techniques available to treat occlusive disease have emerged and this has resulted in a shift from open surgical revascularization to percutaneous endovascular therapy as a first option. We report a 62 years old female patient with diabetes mellitus with poorly healing left lower limb wound and a history of intermittent claudication in both lower limbs, who had chronic total occlusion of the left popliteal artery which was opened employing a drug eluting stent (DES) and drug coated balloon (DCB).

Keywords: Peripheral arterial disease, Peripheral vascular interventions, Critical limb ischemia, chronic total occlusion

Introduction

Endovascular interventions for PAD mainly focused on the descending aorta, iliac, femoral and popliteal arteries. Peripheral vascular intervention (PVI) offers a much lower periprocedural risk. This prevents major amputation of a limb which is associated with loss of independence, diminished quality of life, and poor overall survival. Critical limb ischemia defined as presence of ischemic rest pain, ulceration, or gangrene caused by critically diminished perfusion attributable to occlusive arterial disease and is usually associated with an Ankle-Brachial Index (ABI) <0.4 and toe pressure <30 mm Hg (Rutherford–Baker stages 4–6 and Fontaine stages III and IV). Intermittent claudication (IC) typically presents as leg cramping with exercise that is relieved by rest. The claudication distance gradually decreases with progression of the disease. Femoro-popliteal (Fem-Pop) region is the longest artery with fewest side branches, and the most common location of occlusive disease precipitating IC. Self-expanding stents, drug eluting stents and drug coated balloon (DCB) angioplasty are the mainstay of treatment strategies in managing fem-pop lesions.

Case History

62 years old female with diabetes mellitus for 15 years duration had IC of 6 months duration. She had undergone amputation of four lateral toes and developed a non-healing ulcer at the surgical incision, which had poorly responded to both medical and surgical adjunct therapies. She was determined to be in Rutherford–Baker stage 5 with ischemic ulceration limited to digits. She had no other clinically significant occlusive arterial diseases elsewhere and diabetes was controlled (HbA1C- 7.5%) with insulin therapy.

On examination she had absent dorsalis pedis, popliteal and posterior tibial artery pulsation with ABI of 0.6. Left foot ulcer noted without granulation tissue. Bilateral lower limb arterial duplex revealed severe occlusive arterial disease at both fem-pop regions.

Peripheral Intervention

Via right femoral retrograde puncture (6FG), left leg angiography was performed, which identified a distal popliteal chronic total occlusion (CTO) with bridging collaterals (Image 1).

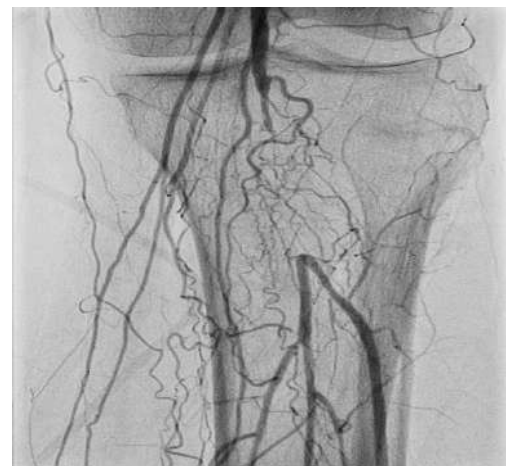

Image 1 - Distal popliteal artery CTO with bridging collaterals

Left femoral artery antegrade access was gained via 6FG vascular sheath and CTO site engaged with Judkin Right (JR) 3 guide catheter. CTO was crossed with Fielder XT (0.014") coronary guide wire with FineCross micro-catheter support. Wire exchanged to Asahi Sion guidewire (0.014"). Lesion predilated with Sapphire 2.5x12 mm normal pressure balloon at 8 atm (Image 2).



Proximal popliteal artery over the knee joint area was treated with In.Pact Falcon Paclitaxel coated balloon at 8 atm (Image 3).

CTO segment stented with Xience Prime 2.75x38 mm Everolimus eluting stent at 10 atm (Image 4).

Post procedure angiogram revealed excellent results with brisk 3 vessel run off (Image 5)

Patient made an uneventful recovery and ABI fell to 0.8 at 24 hours. Her lower limb wound completely healed 4 weeks after post procedure (Image 6) and she remains asymptomatic at 6 months.

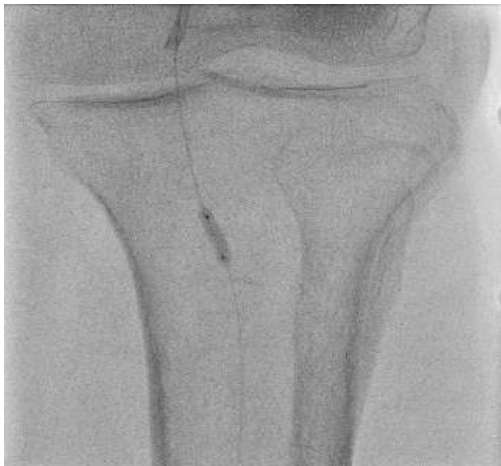

Image 2 – Pre-dilatation of CTO segment

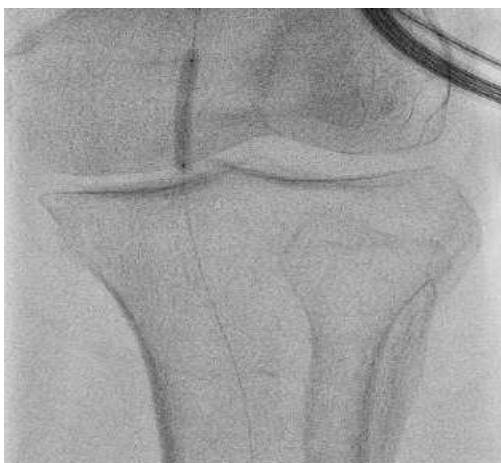

Image 3 – Proximal popliteal artery dilatation with Paclitaxel eluting balloon

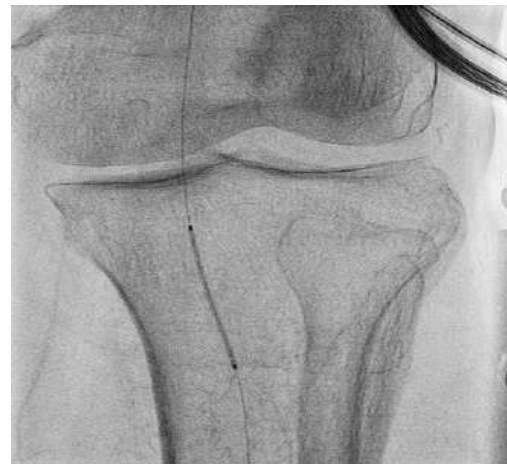

Image 4 – CTO segment stenting with Everolimus eluting coronary stent (2.75x33 mm)

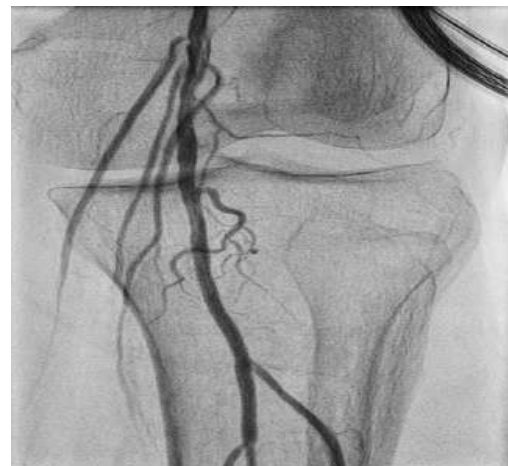

Image 5- Final angiogram with good distal run off

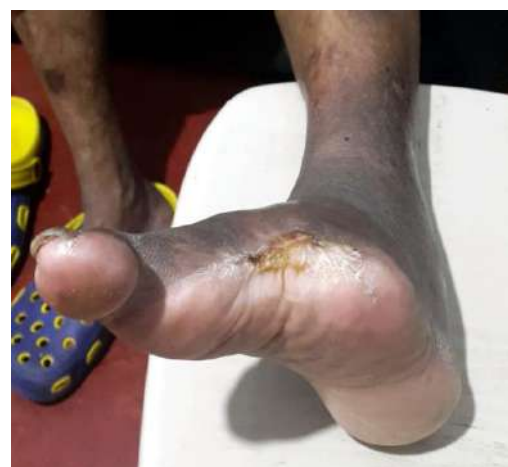

Image 6- Healed surgical site wound one month after procedure



Discussion

Endovascular therapy is now established to treat lower-extremity peripheral arterial diseases including CTO ⁽¹⁾, as an alternative to surgical revascularization ⁽²⁾. Even though patients are benefitted by low perioperative risk and less hospital stay compared to surgical interventions ^(3,4), a number of procedural complications as well as long term complications have been described with PVI. Arterial dissection, perforations, vascular access haematoma formation are seen immediately and re-stenosis, stent fracture and dislocation are seen later. Popliteal artery is an area of high mechanical stress and dynamic force which has been associated with accelerated restenosis and high rates of stent fracture and occlusion. Although newer stents improved outcomes in this territory, in-stent restenosis is still recognized as a challenging complication in patients with PAD ⁽⁵⁾. Use of DES over bare metal stents has shown superior outcome with higher patency rate ⁽⁶⁾. DCB potentially benefit by avoiding stenting where there is a high risk of stent fracture, occlusion and long term dual anti platelets. Re-stenosis rates were lower in DCB over plain balloon angioplasty ^(7,8). In our patient, advance precautions which we have taken led to an uncomplicated procedure. The strategy which we have employed in this patient by avoiding stenting at the knee joint and use of DCB instead will lead to long term patency rate. Post procedural care and surveillance should target the durability of the endovascular procedure with a multi-disciplinary approach. Promotion of regular exercise, control of vascular risk factors, continuation of drug treatment, periodic assessment of vessel patency and timely re-intervention are vital in the post-operative management. In our patient dual anti-platelet therapy was advised for one year followed by aspirin alone lifelong with continuous surveillance.

References

1. K.A. Gallagher, A.J. Meltzer, R.A. Ravin, A. Graham, G. Shrikhande, P.H. Connolly, et al. Endovascular management as first therapy for chronic total occlusion of the lower extremity arteries: comparison of balloon angioplasty, stenting, and directional atherectomy. *J Endovasc Ther*, 18 (2011), pp. 624-637
2. Rowe VL, Lee W, Weaver FA, Etzioni D. Patterns of treatment for peripheral arterial disease in the United States: 1996-2005. *J Vasc Surg*. 2009; 49:910-91
3. A.W. Bradbury, D.J. Adam, J. Bell, J.F. Forbes, F.G. Fowkes, I. Gillespie, et al., BASIL trial Participants Bypass versus Angioplasty in Severe Ischaemia of the Leg (BASIL) trial: An intention-to-treat analysis of amputation-free and overall survival in patients randomized to a bypass surgery-first or a balloon angioplasty-first revascularization strategy *J Vasc Surg*, 51 (5 Suppl) (2010), pp. 5-17S
4. N.N. Egorova, S. Guillerme, A. Gelijns, N. Morrissey, R. Dayal, J.F. McKinsey, et al. An analysis of the outcomes of a decade of experience with lower extremity revascularization including limb salvage, lengths of stay, and safety *J Vasc Surg*, 51 (2010), pp. 878-885
5. Parthipun A, Diamantopoulos A, Kitrou P, et al. Use of a new hybrid heparin-bonded nitinol ring stent in the popliteal artery: procedural and mid-term clinical and anatomical outcomes. *Cardiovasc Intervent Radiol*. 2015; 38:846-854
6. De Cock E, Sapoval M, Julia P, de Lissoyoy G, Lopes S.A budget impact model for paclitaxel-eluting stent in femoropopliteal disease in France. *Cardiovasc Intervent Radiol*. 2013; 36:362-370. doi: 10.1007/s00270-012-0494-x.
7. Tepe G, Zeller T, Albrecht T, Heller S, Schwarzwälder U, Beregi JP, Claussen CD, Oldenburg A, Scheller B, Speck U. Local delivery of paclitaxel to inhibit restenosis during angioplasty of the leg. *N Engl J Med*. 2008; 358:689-699. doi: 10.1056/NEJMoa0706356.
8. Werk M, Albrecht T, Meyer DR, Ahmed MN, Behne A, Dietz U, Eschenbach G, Hartmann H, Lange C, Schnorr B, Stiepani H, Zoccai GB, Hänninen EL. Paclitaxel-coated balloons reduce restenosis after femoro-popliteal angioplasty: evidence from the randomized PACIFIER trial. *Circ Cardiovasc Interv*. 2012; 5:831-840. doi: 10.1161/CIRCINTERVENTIONS.112.971630.



Case Report

A 27-year-old Lady with Non-atherosclerotic Spontaneous Left Anterior Descending Coronary Artery Dissection

Prabath IHDS¹, Fernando N¹, Pereira T¹

1. Institute of Cardiology, National Hospital of Sri Lanka.

Corresponding Author: Dr. I.H.D.S. Prabath

Email: sandunprabath@gmail.com

Abstract

We report a young lady who presented with non-atherosclerotic spontaneous LAD coronary artery dissection who was managed with percutaneous coronary intervention after failed conservative approach. The utility of intravascular ultrasound technology in diagnosis, management and the technically difficult nature of interventional approach in arterial dissection are highlighted.

Keywords: Non-atherosclerotic coronary artery dissection, Coronary dissection

Introduction

Non-atherosclerotic Spontaneous Coronary Artery Dissection (NASCAD) is the term used to indicate a non-traumatic and non-iatrogenic separation of the coronary arterial wall possibly due to either an intimal tear or a bleeding of vasa vasorum, resulting in an intra-medial hemorrhage. In contrast to atherosclerotic SCAD which is limited in extent by medial atrophy and scarring, NASCAD can involve extensive lengths. SCAD is a rare cause for acute coronary syndrome (ACS) with a reported incidence of 0.1-4 % of cases in the general population⁽¹⁾. Nearly a quarter of ACS in women less than fifty years are noted to be due to SCAD. The possible predisposing factors identified for NASCAD are post-partum status, fibro-muscular dysplasia (FMD), hormonal therapy, multiparity (>4 births), systemic inflammatory conditions and connective tissue disorders⁽²⁾.

Case Presentation

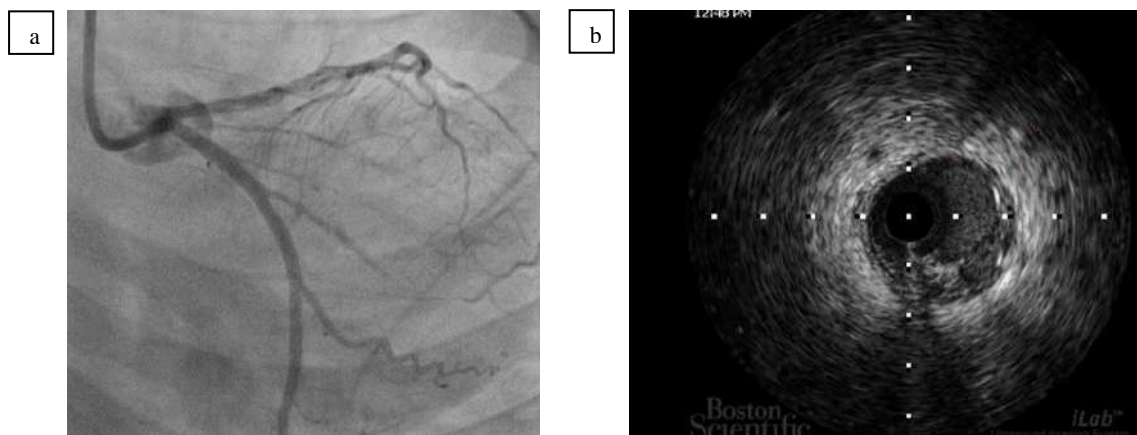
A 27-year-old mother of two who was previously well, had presented to the local hospital with acute ischemic chest pain of one day duration. She was diagnosed to have Non-ST Elevation Myocardial Infarction (NSTEMI) with inferior territory involvement. She was transferred to the Institute of Cardiology, National Hospital of Sri Lanka (NHSL) for further management.

On presentation to NHSL, patient was complaining of persistent chest pain and ECG showed sinus bradycardia with biphasic T in leads aVL, II, III and aVF.

Her echocardiogram showed good systolic and diastolic functions without any wall motion abnormality while troponin I was rising from 1.4 to 8.6 ng/mL. An emergency coronary angiogram was performed which showed a spontaneous Left Anterior Descending Coronary Artery (LAD) dissection with a TIMI III distal flow (Figure 1a). The rest of the coronary circulation was normal. It was decided to manage the patient medically and she was discharged after a course of LMWH once the ischemic chest pain completely resolved with minimal ECG changes.

One week later, the patient was complaining of class III angina and was readmitted for further evaluation and management. An urgent repeat angiography showed the same proximal to mid vessel dissection of the LAD. An intravascular ultrasound scan (IVUS) was performed over the dissected segment of LAD. The dissection flap of 29mm in length proximal to D1 was visualized (Figure 1b). An ostial to proximal LAD stenting with a Drug Eluting Stent was done. The post stenting IVUS showed optimal stent deployment and the post stenting angiography revealed TIMI III flow in LAD and all its' branches.

The patient had a significant improvement of her symptoms soon after the procedure and she was free of angina on discharge. The patient was kept on a beta blocker with DAPT and referred to a gynecologist for a permanent method of contraception after explaining the high risk for pregnancy.



**Figure 1- (a) Left Anterior Descending Coronary Artery (LAD) dissection with a TIMI III distal flow
(b) The dissection flap of 29mm in length proximal to D1**

Discussion

NASCAD mainly manifests with typical characteristic symptoms and signs of myocardial infarction which yet can have diverse presentations. The most frequently affected vessel is LAD⁽³⁾. The corner stone of the diagnosis of NASCAD is the coronary angiography. A high degree of suspicion is needed in the proper context to plan for further evaluation with optical coherence tomography (OCT) or IVUS. Alternatively, the coronary angiography could be repeated in 4-6 weeks to detect the spontaneous healing of the dissected segment.

If the patient is clinically stable with a non-critical luminal obstruction and a TIMI III distal flow, conservative approach is recommended in most spontaneous SCAD. However, patients presenting with ACS with ongoing symptoms of ischemia and/or haemodynamic compromise must be considered for revascularization⁽⁴⁾.

In this case, we undertook latter approach even though the PCI is technically challenging associated with higher complication rates and failure in SCAD. The patients with SCAD will benefit from long term DAPT, a beta blocker and a statin if dyslipidemia is present. A reduced recurrence of SADC is observed with the usage of a beta blocker⁽⁵⁾.

Conclusion

A high index of suspicion is important in the diagnosis of NASCAD, where a conservative approach is preferred over revascularization strategy when appropriate.

References

1. Hayes SN, Kim ESH, Saw J, et al. Spontaneous Coronary Artery Dissection: Current State of the Science: A Scientific Statement from the American Heart Association. *Circulation*, 2018; 137: e523.
2. Saw J, Aymong E, Sedlak T, et al. Spontaneous coronary artery dissection: association with predisposing arteriopathies and precipitating stressors and cardiovascular outcomes. *Circ Cardiovasc Interv*, 2014; 7:645.
3. Tweet MS, Hayes SN, Pitta SR, et al. Clinical features, management, and prognosis of spontaneous coronary artery dissection. *Circulation*, 2012; 126: 579.
4. Hayes SN, Kim ESH, Saw J, et al. Spontaneous Coronary Artery Dissection: Current State of the Science: A Scientific Statement from the American Heart Association. *Circulation*, 2018; 137: e523.
5. Saw J, Humphries K, Aymong E, et al. Spontaneous Coronary Artery Dissection: Clinical Outcomes and Risk of Recurrence. *J Am Coll Cardiol*, 2017; 70: 1148.



Case Report

Idiopathic Calcific Constrictive Pericarditis, successfully treated with Surgical Pericardiectomy

N.U.A. Dissanayake¹, Gamini Galappatthy¹, A.K Pathirana¹, Rajitha Y De Silva², C.I.H. Siriwardane¹, I.U.K. Marasinghe¹

¹ Institute of Cardiology, National Hospital of Sri Lanka.

² Cardio thoracic unit, Sri Jayawardhanapura General Hospital,

Corresponding author: Dr. N.U.A. Dissanayake

E-mail: nuajithdissanayake@gmail.com

Abstract

Constrictive pericarditis is a potentially curable condition caused by different aetiologies. It is an uncommon entity in clinical practice and challenging to diagnose. Therefore, a high degree of clinical suspicion and use of multimodality imaging approach is required to achieve a diagnosis. Herein, we present a case of idiopathic calcific constrictive pericarditis, which was diagnosed with the help of multimodality imaging approaches such as two dimensional echocardiography and computed tomographic scan. The patient presented with features of right heart failure. There was failure of response to initial medical therapy with diuretics, however his symptoms improved dramatically after surgical pericardiectomy. This case demonstrates the classic presentation of constrictive pericarditis, investigation required and their findings to diagnose, and provides a discussion of the benefit and outcomes of prompt treatment.

Key words: Constrictive pericarditis, Constrictive physiology, Mitral annular motion, Pericardiectomy, Right heart failure.

Introduction

Constrictive pericarditis (CP) is a relatively uncommon entity leading to clinical heart failure, which is characterized by an inflammatory process that leads to progressive fibrous thickening or/and calcification of the pericardium resulting in pericardial non-compliance. The presence of pericardial calcification is a cardinal feature of CP. However the absence of it does not exclude the diagnosis ⁽¹⁾. The most common identifiable cause of CP are tuberculosis, previous open heart surgery and mediastinal irradiation ⁽²⁾. Other possible causes include connective tissue diseases, malignancy, chronic renal failure, trauma and infections ⁽¹⁾. However, more than half of cases are idiopathic with no identifiable cause found ⁽¹⁾.

The diagnosis of constrictive pericarditis has been challenging even though multiple diagnostic modalities have been developed. However, because it is potentially reversible, the diagnosis must not be missed. Surgical pericardiectomy has the ability to cure CP, with dramatic improvements in symptoms and quality of life ^(2,3).

Case report

A 32-year-old previously healthy male presented with fatigue, gradually worsening dyspnea on exertion, abdominal distention and pedal edema for more than one year duration. There was no history of fever or cough.

The physical examination revealed peripheral edema, gross ascites and elevated jugular venous pressure. The precordial examination revealed a normal heart size and diminished heart sounds with a pericardial knock. Routine blood examination including full blood count (FBC) and liver function test results were normal with normal inflammatory markers. An electrocardiogram showed a normal sinus rhythm with a heart rate of 90 beats/min. Two dimensional echocardiography (2D Echo) revealed severe calcification of both parietal and visceral pericardium with thin pericardial effusion and preserved left ventricular ejection fraction (EF). Both left and right atria were dilated with plethoric inferior vena cava. Doppler study showed constrictive physiology of the mitral valve with increased E-wave velocity and shortened deceleration time with a small A-wave. Tissue Doppler image revealed preserved early diastolic mitral annular velocity (e') with the ratio between lateral and septal mitral annulus as well as tricuspid annulus being significantly reduced.

The chest radiograph (CXR) revealed diffuse and dense calcification of the pericardium without evidence of old or active tuberculosis. A thoracic computed tomographic (CT) scan demonstrated a calcific pericardium surrounding the entire heart involving both parietal and visceral pericardium.

Case Report

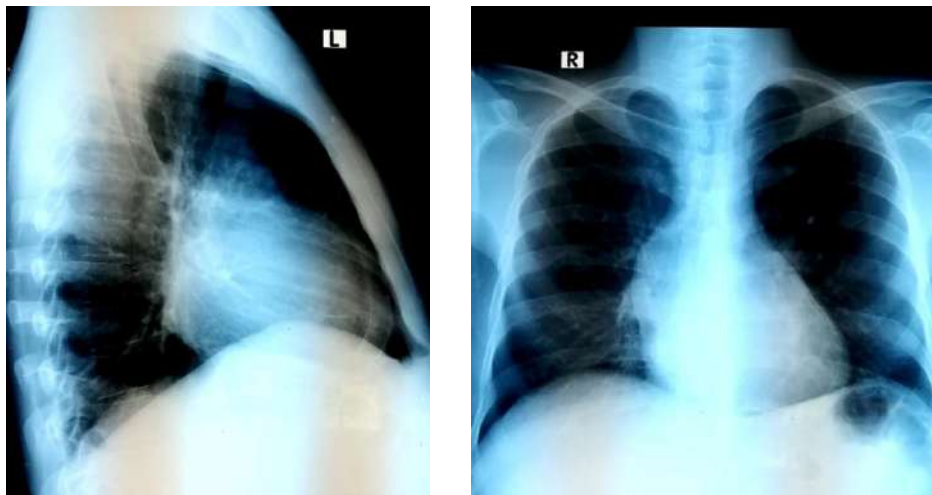


Figure 1: Chest X-ray lateral and PA views – Pericardial calcification

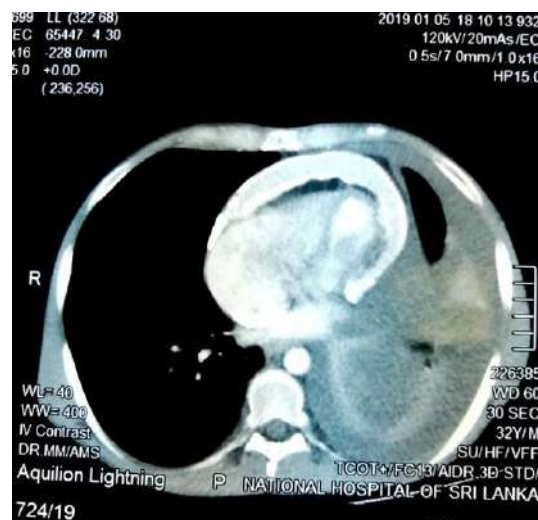


Figure 2: CT chest – Pericardial calcification

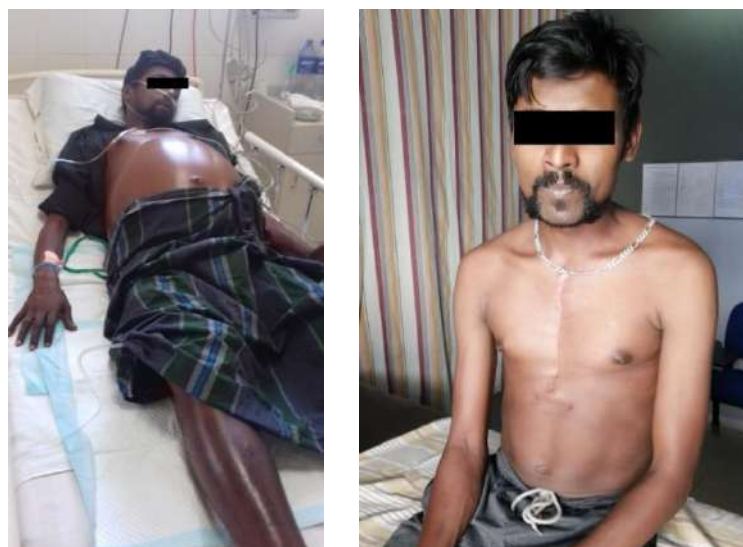

Figure 3: Before and after the surgical pericardiectomy



The consent for surgery was given by the patient due to continued deterioration of his clinical condition with features of severe right heart failure leading to poor quality of life while on medical management. Successful surgical pericardiectomy was done without major complications and patient had dramatic improvement of his symptoms and quality of life.

Discussion

Constrictive pericarditis is a condition, which leads to decreased compliance of the pericardium due to pericardial thickening and fibrosis with or without calcification. This may result in impaired ventricular diastolic filling and right heart failure⁽¹⁾. The most common causes of constrictive pericarditis are idiopathic and followed by previous cardiac surgery and mediastinal irradiation⁽²⁾. Tuberculous pericarditis is an important aetiology in developing countries.

The symptoms of CP develop slowly over a number of years and there are no clinical features specific to CP. The classical presentation of constrictive pericarditis is similar to symptoms and signs of chronic right heart failure (RHF). Fatigue, dyspnea on exertion, orthopnea, lower leg oedema, hepatic congestion with subsequent development of ascites, abdominal discomfort, anasarca, and jaundice are the common clinical manifestation of CP. However, other cardiac and non cardiac diseases can present with similar symptoms, specially restrictive cardiomyopathy and tricuspid valve dysfunction can cause signs and symptoms of right heart failure similar to CP⁽⁴⁾. Therefore high degree of clinical suspicion⁽⁵⁾ and multimodality imaging approach⁽¹⁾ is needed to evaluate a patient with symptoms of RHF to diagnose CP.

Echocardiography would be considered as the first-line diagnostic modality and constrictive pericarditis should be suspected in patients presenting with heart failure symptoms and preserved ejection fraction as in our patient. Respiration-related ventricular septal shift, restrictive mitral inflow velocity (E/A ratio > 0.8), preserved or accelerated medial mitral annular motion (e'velocity > 9cm/sec), reversal of the relationship between lateral to medial annular tissue Doppler velocities (also called annulus reversus).

Hepatic vein expiratory diastolic reversal and plethoric inferior vena cava^(6,7) should alert the interpreting clinician to the diagnosis of CP. Although these Doppler findings are usually diagnostic, both false-positive and false-negative results exist. Therefore single echocardiographic parameter should not be used exclusively to diagnose CP rather than multifaceted approach.

Even though echocardiography is not considered as a reliable technique to visualize the pericardium, CT and magnetic resonance (MR) imaging can directly demonstrate the morphology of pericardium. Therefore CT and MRI are recommended in the assessment of pericardial morphology in CP, which revealed generalized pericardial thickening and pericardial calcifications⁽¹⁾. In patients with appropriate clinical manifestations, pericardial thickness of >5 to 6 mm is highly specific and >4 mm is suggestive of pericardial constriction⁽¹⁾. But the absence of pericardial thickening does not exclude the diagnosis, because up to 20% of patients with surgically confirmed constrictive pericarditis showed normal pericardial thickness on imaging studies⁽⁵⁾.

Pericardial calcifications are an important finding in imaging study, which is highly suggestive of constrictive pericarditis⁽⁸⁾, regardless of the degree of pericardial thickening.

Our patient presented with classic symptoms and signs of right heart failure and the transthoracic echocardiogram revealed right heart failure with constrictive physiology of the mitral and tricuspid valves. A chest radiograph showed pericardial calcification, and the chest CT confirmed the diagnosis with pericardial thickening and calcification.

The primary goal in management of CP is to improve cardiac function, haemodynamic and symptoms. It is crucial to identify the primary aetiology and be managed accordingly. The definitive treatment for CP is complete surgical pericardiectomy and should be carried out whenever feasible⁽⁹⁾.

Pericardiectomy generally cure the CP with rapid haemodynamic and symptomatic improvements in most patients.



At present, with improved technique and skill, pericardiectomy is generally a safe procedure, although the early post-operative death risk is more than 2%. Survival rates vary from 55% to 90% on the basis of age, sex, and race ⁽¹⁰⁾.

Even though medical management of CP remains controversial, careful observation and symptomatic treatment, has been suggested in less severe cases. A strict fluid restriction, low sodium diet and diuretics have been used in the early stages of the disease to improve pulmonary and systemic congestion. However, diuretics should be used cautiously as any drop in intravascular volume may lead to a significant drop in cardiac output.

Medical management was unsuccessful in our patient. A medically treatable aetiology could not be identified despite extensive investigations. Therefore, the best option for the management of our patient was complete surgical pericardiectomy in view of complete cure.

Conclusion

The diagnosis of constrictive pericarditis is still challenging. High degree of clinical suspicion, multimodality imaging approach including echocardiogram, chest radiography, CT and MRI are needed for more accurate diagnosis and to decide the optimal treatment option for patients with constrictive pericarditis. When there is no medically treatable aetiology, surgical pericardiectomy is the best treatment option which can cure CP.

References

1. Bogaert J, Francone M. Pericardial disease: value of CT and MR imaging. *Radiology*, 2013; 267:340-356. doi: 10.1148/radiol.13121059. [PubMed] [CrossRef]
2. Ling LH, Oh JK, Schaff HV, Danielson GK, Mahoney DW, Seward JB, Tajik AJ. Constrictive pericarditis in the modern era: evolving clinical spectrum and impact on outcome after pericardiectomy. *Circulation*, 1999; 100: 1380-1386. doi: 10.1161/01.CIR.100.13.1380. [PubMed] [CrossRef]
3. Geske JB, Anavekar NS, Nishimura RA, Oh JK, Gersh BJ. Differentiation of constriction and restriction: complex cardiovascular hemodynamics. *J Am Coll Cardiol*, 2016; 68: 2329-47.
4. Bergman M, Vitrai J, Salman H. Constrictive pericarditis: a reminder of a not so rare disease. *Eur Intern Med*, 2006; 17: 457-464. doi: 10.1016/j.ejim.2006.07.006. [PubMed] [CrossRef]
5. Nishimura RA. Constrictive pericarditis in the modern era: a diagnostic dilemma. *Heart*, 2001; 86: 619-623. doi:10.1136/heart.86.6.619. [PMC free article] [PubMed] [CrossRef]
6. Oh JK, Tajik AJ, Appleton CP, Hatle LK, Nishimura RA, Seward JB. Preload reduction to unmask the characteristic Doppler features of constrictive pericarditis: a new observation. *Circulation*, 1997; 95: 796-9.
7. Reuss CS, Wilansky SM, Lester SJ, et al. Using mitral 'annulus reversus' to diagnose constrictive pericarditis. *Eur J Echocardiogr*, 2009; 10: 372-5.
8. Isner JM, Carter BL, Bankoff MS, Konstam MA, Salem DN. Computed tomography in the diagnosis of pericardial heart disease. *Ann Intern Med*, 1982; 97: 473-479. doi: 10.7326/0003-4819-97-4-473. [PubMed] [CrossRef]
9. Glenn F, Diethelm A. Surgical treatment of constrictive pericarditis. *Ann Surg*, 1962; 155: 883-93.
10. Yetkin U, Ilhan G, Calli AO, Yesil M, Gurbuz A. Severe calcific chronic constrictive tuberculous pericarditis. *Tex Heart Inst J*, 2008; 35: 224-5.



Case Report

Inferior STEMI due to acute occlusion of an anomalous left circumflex artery arising from the right coronary cusp and percutaneous coronary intervention of the anomalous culprit coronary artery

Boralessa MDS¹, Sampath Withanawasam¹

¹. Institute of cardiology, National Hospital Sri Lanka (NHSL), Colombo

Corresponding Author: Dr. M.D.S. Boralessa

Email: mahenbora1984@gmail.com

Abstract

The anomalous origin of the left circumflex artery as an independent branch from the right coronary cusp is a rare variation. These patients may rarely present with acute coronary syndrome. Therefore, the identification of the culprit lesion and its treatment may be difficult, particularly in the emergency setting of primary or rescue percutaneous coronary interventions (PCI). We report a case of a 40-year-old male, who underwent rescue PCI to an anomalous left circumflex artery following failed thrombolysis upon presentation with an inferior ST elevation myocardial infarction (STEMI) to a rural hospital. This case demonstrates the technical challenges encountered in making the diagnosis, to enable life saving treatment.

Keywords: Anomalous origin of coronary artery, Anomalous origin of the left circumflex artery, Inferior STEMI, Percutaneous coronary intervention

Case Report

A 40-year-old previously healthy male presented to the District General Hospital, Embilipitiya following the development of chest pain. The patient had been admitted within 30 minutes of the onset of pain. An immediate bed side electro cardiogram (ECG) revealed changes suggestive of an inferior STEMI.

The patient was hemodynamically stable with no features of cardiac failure or cardiac rhythm disturbances. He was treated with thrombolytic therapy with standard dosage of intra vascular (IV) Streptokinase. However, he had poor response to medical management, remained symptomatic and was transferred for rescue PCI to the Cardiology unit, NHSL, Colombo via a hospital ambulance transfer, a journey that lasted 5 hours.

Upon arrival to the Cardiology unit, NHSL an echocardiogram performed revealed hypokinesia of the inferior segments of the heart suggestive of ongoing ischemia. Thereafter, the patient underwent coronary angiography to determine the etiology of ischemia.

Angiography of the right coronary artery (RCA) did not reveal an obvious culprit lesion (Figure 1).

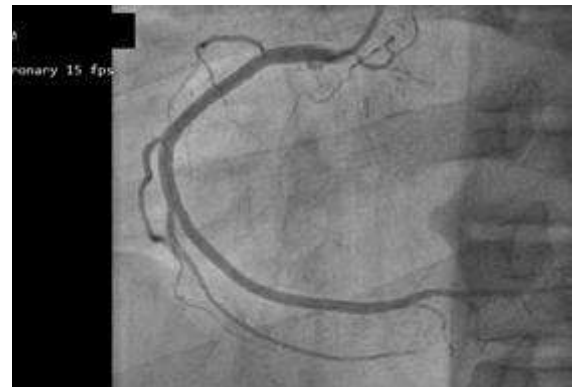

Figure 1: Angiography of the right coronary artery

Thereafter, engagement and angiography of the left coronary artery was performed (Figure 2, “Spider view” of left coronary artery). However, there was no culprit lesion noted on the left system.

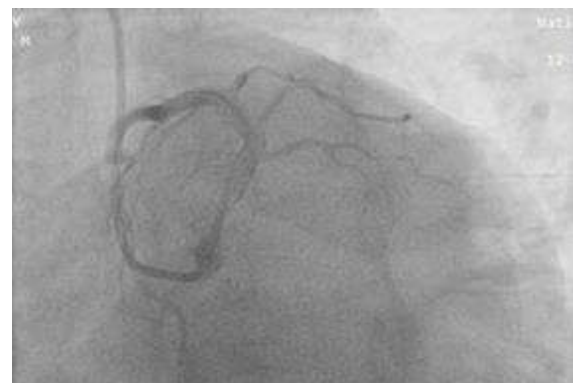

Figure 2: “Spider view” of left coronary artery



Case Report

Despite what appeared to be a small caliber left circumflex artery, there was high suspicion of the presence of a left circumflex artery with an anomalous origin due to the following reasons,

1. Presence of ongoing chest pain
2. ECG changes suggestive of Inferior STEMI
3. 2D echo changed suggestive of inferior wall hypokinesia
4. High titre of Troponin I

Therefore, an angiography of the aortic root was performed with the use of a pig tail catheter. This revealed, a large caliber left circumflex artery with an anomalous origin from the right coronary cusp as an independent branch. (Figure 3)

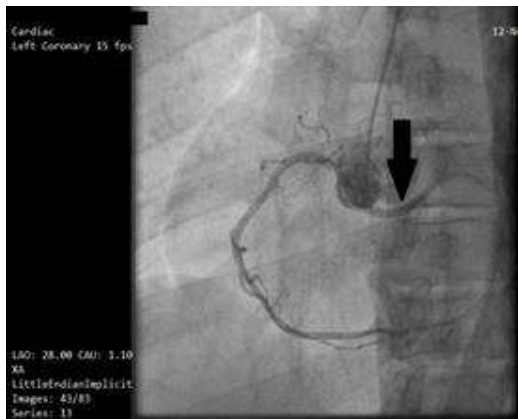


Figure 3: large caliber left circumflex artery with an anomalous origin from the right coronary cusp as an independent branch

The Left circumflex artery was engaged with a 6F Judkins Right (JR) catheter and upon angiography was noted to have a near total occlusion at its mid segment (Figure 4). Thereafter the patient underwent PCI. A SION guidewire was used to cross the culprit lesion. The lesion was pre-dilated with a Mozec 2.0 x 8mm balloon at 4 atm (Figure 5). A Xience Prime 2.75 x 18mm drug eluting stent (DES) was deployed over the lesion at 10 atm.

Post dilation of the stent was performed with NC Mozec 2.75 x 8mm balloon at 10 – 14 atm. Successful reperfusion was achieved with TIMI III flow and absence of complications (Figure 6). The patient underwent an uneventful recovery and was discharged 2 days after PCI. He is at present receiving follow up care at DGH Embilipitiya.

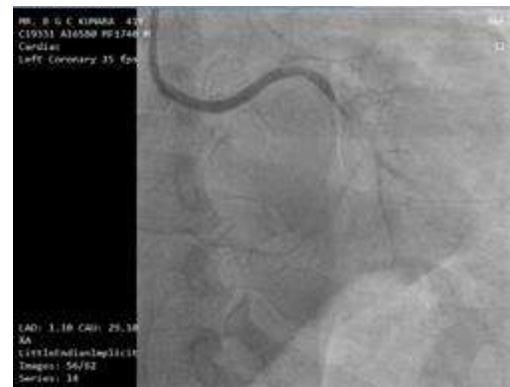

Figure 4: Left circumflex artery near total occlusion at its mid segment

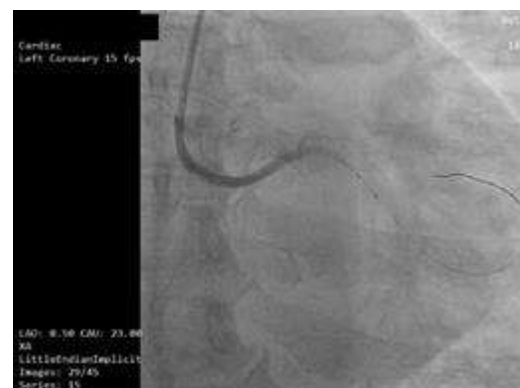

Figure 5: The lesion was pre-dilated with a Mozec 2.0 x 8mm balloon at 4 atm

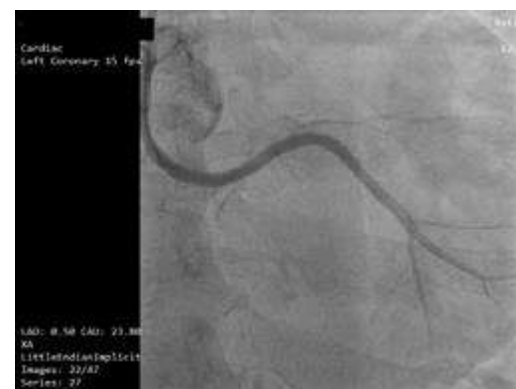

Figure 6: Successful reperfusion was achieved with TIMI III flow



Discussion

Anomalous origin of the coronary artery is rare. The clinical importance of this anomaly is evident from its association as a manifestation of myocardial ischemia ⁽¹⁾.

Anomalous origin of culprit coronary artery (AOCCA) may either be difficult to diagnose and can be missed. It can be technically difficult to perform PCI even in STEMI ⁽²⁾.

Anomalous origin of the left circumflex artery may be classified according to the site of origin into different subtypes: left circumflex artery arising as a direct branch from the right coronary artery (RCA), a common right system ostium bifurcating into the left circumflex artery and RCA, and, as in our case, RCA and left circumflex artery originating from two separate orifices ⁽³⁾.

Our patient had classic onset of ischemic type chest pain along with supportive evidence of cardiac ischemia by inferior segment ST elevations on his ECG, elevated troponin I, echocardiography evidence of inferior wall hypokinesia and coronary angiography that revealed near total occlusion of anomalous left circumflex coronary artery. Despite a delay due to transfer to reach a PCI facility from a rural hospital, he underwent PCI that produced satisfactory results and made a good recovery.

Conclusion

This case highlights the need to be vigilant while evaluating angiography for culprit lesions in the management of acute coronary syndrome patients.

It also highlights the need for development of regional (Provincial/District) cardiac centers with PCI facilities for management of cardiac patients and to avoid undue delays in providing care.

References

1. Samarendra P, Kumari S, Hafeez M, et al. Anomalous circumflex coronary artery: benign or predisposed to selective atherosclerosis. *Angiology*, 2001; 52: 521-6
2. Tyczynski P, Kukula T, et al. Anomalous origin of culprit coronary arteries in acute coronary syndromes. *Cardio J*, 2018; 25(6): 683-690
3. Antopol W, Kugel MA. Anomalous origin of the left circumflex coronary artery. *Am Heart J*, 1933; 8: 802-6.



Case Report

Rotational Atherectomy (Rotablator) assisted successful PCI in a Heavily Calcified and Stenosed Right Coronary Artery

Wickramarachchi CP¹, Gambhir S², Lokuketagoda K¹, Herath J¹, Amarasena N¹

1. Sri Jayewardenepura General Hospital, Sri Lanka.

2. Kailesh University Hospital, India

Corresponding Author: Dr. C P Wickramarachchi

E-mail: chintaka1985@gmail.com

Abstract

Heavily calcified coronary arteries carry a formidable challenge in percutaneous coronary interventions. Optimum lesion preparation plays a key role in both immediate as well as long term clinical outcome in percutaneous coronary interventions in heavily calcified coronary arteries. Novel devices have markedly improved in their efficacy in delivering excellent results in this aspect. We report a case of successful Rotablator assisted percutaneous coronary intervention done to a patient who admitted with acute NSTEMI. His Left ventricular ejection fraction was 50% with inferior wall hypokinesia. His coronary angiogram revealed critical stenosis in mid RCA which was a heavily calcified vessel. Thus we decided to use the Rotablator to prepare the lesion properly prior to the coronary intervention. We achieved excellent stent apposition with TIMI 3 flow in distal RCA with resolution of clinical symptoms.

Keywords: Calcific coronary artery, rotational atherectomy,

Case report

A 62-year-old patient with diabetes mellitus and dyslipidaemia presented with ischaemic chest pain to the cardiac ward. She was haemodynamically stable with clear lung bases. Her ECG revealed ST depressions in inferior leads with elevated troponin titer. 2 D echocardiogram revealed ejection fraction of 50% with inferior wall hypokinesia. She was treated with loading doses of dual antiplatelet agents and subcutaneous heparin. Her chest pain subsided.

Next day, coronary angiography was performed and it showed heavily calcified right coronary artery with 99% stenosis at mid vessel and another 90% stenosis at the crux involving proximal PDA. Left main and left anterior descending arteries were normal. Left circumflex artery had minor proximal disease.

Considering the heavily calcified nature of RCA, rotablator assisted PCI technique was decided. Right femoral puncture was made and 8 Fr sheath inserted. Temporary pace maker was kept in situ. 7 Fr Amplatz 1 catheter was used to engage right coronary ostia. Initially, lesions were crossed with Sion blue wire and microcatheter assisted wire exchange was done to rotablator floppy wire. Rotablator functions were checked and several runs of rotablation done using 1.25mm burr, in mid vessel and distal lesions. Several cycles were performed using 1.5mm burr. Slow flow was noted in distal RCA and corrected with intracoronary nitrate and adenosine. Both lesions were predilated with 2.0×12 mm semi compliant balloon.

Subsequently both distal and mid vessel lesions were successfully stented and post dilatation done using non-compliant balloon up to 20 ATM. TIMI 3 flow was established in RCA and branches.

Discussion

Percutaneous coronary interventions of heavily calcified coronary vessels still present an enormous challenge in interventional cardiology, with higher risk of immediate complications such as coronary perforation, late failure due to stent under expansion and malposition, and consequently stent restenosis and poor clinical outcome. Good characterization of calcium distribution with multimodal imaging is important to improve the success of treatment. Optimum lesion preparation is one of the key factors for the success of such lesions. Therefore, technology has improved in many ways to develop new tools and devices. Rotablator (rotational atherectomy), orbital atherectomy, laser treatment and coronary intravascular lithotripsy are promising and emerging techniques in the field of calcified coronary arteries. Rotational atherectomy is relatively cost effective device with a reasonable learning curve. Most of the time it gives successful results though it may cause complications such as coronary artery dissections and burr getting entrapped. However optimum lesion preparation in calcified coronary arteries using standard coronary debulking device will give better short term as well as long term clinical results. Delivering coronary devices to the required stenosed segment becomes easier after using the rotablator.

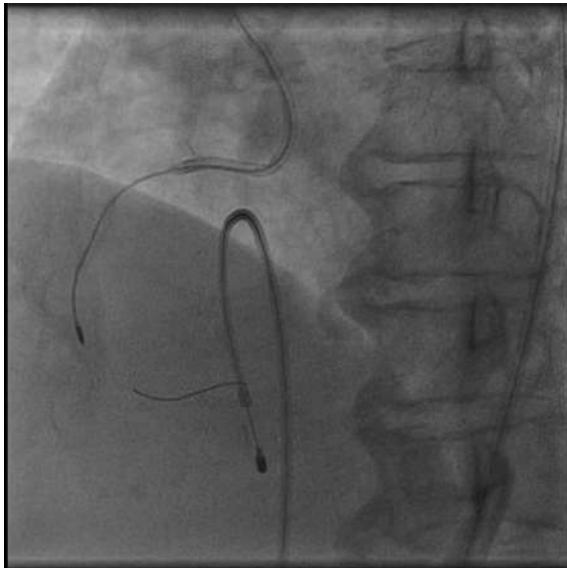


Figure 1: A stage during procedure

References:

1. Bittl JA, Chew DP, Topol EJ, Kong DF, Califf RM. Metaanalysis of randomized trials of percutaneous transluminal coronary angioplasty versus atherectomy, cutting balloon atherotomy, or laser angioplasty. *J Am Coll Cardiol.* 2004;43:936–42. doi: 10.1016/j.jacc.2003.
2. Moreno R, Conde C, Perez-Vizcayno MJ. Prognostic impact of a chronic occlusion in a noninfarct vessel in patients with acute myocardial infarction and multivessel disease undergoing primary percutaneous coronary intervention. *J Invasive Cardiol.* 2006;18:16.
3. Prasad A, Rihal CS, Lennon RJ, Wiste HJ, Singh M, Holmes DR., Jr. Trends in outcomes after percutaneous coronary intervention for chronic total occlusions: a 25-year experience from the Mayo Clinic. *J Am Coll Cardiol.* 2007;49:1611–8. doi: 10.1016/j.jacc.2006.12.040.
4. Ron Waksman SS. *Chronic Total Occlusions: A Guide to Recanalization* 2nd edition. In: John Wiley & Sons, Ltd, 2013;38;2013.
5. Fefer P, Knudtson ML, Cheema AN. Current perspectives on coronary chronic total occlusions: the Canadian Multicenter Chronic Total Occlusions Registry. *J Am Coll Cardiol.* 2012;59:991–7. doi: 10.1016/j.jacc.2011.12.007. [PubMed]
6. King SB, Yeh W, Holubkov R. Balloon angioplasty versus new device intervention: clinical outcomes. A comparison of the NHLBI PTCA and NACI registries. *J Am Coll Cardiol.* 1998;31:558–66. doi: 10.1016/S0735-1097(97)10523-X.
7. Bittl JA. Directional coronary atherectomy versus balloon angioplasty. *N Engl J Med.* 1993;329:273–4. doi: 10.1056/NEJM199307223290410. [PubMed]
8. Moliterno DJ. Rotational atherectomy for resistant chronic total occlusions: another spin for tough old problems. *Catheter Cardiovasc Interv.* 2010;76:372–3. doi: 10.1002/ccd.22752.
9. Walton AS, Pomerantsev EV, Oesterle SN. Outcome of narrowing related side branches after high-speed rotational atherectomy. *Am J Cardiol.* 1996;77:370–3. doi: 10.1016/S0002-9149(97)89366-6.
10. Tsuchikane E, Suzuki T, Asakura Y. Debulking of chronic coronary total occlusions with rotational or directional atherectomy before stenting: Final results of DOCTORS study. *Int J Cardiol.* 2008;125:397–403. doi: 10.1016/j.ijcard.2007.07.117.



Brief Report

Clinical and Echocardiographic patterns of presentation and Immediate outcomes of Coarctation of aorta patients following Transcatheter intervention in a Tertiary Cardiac Intervention centre in Sri Lanka

Mendis S A E S¹

¹ Institute of Cardiology, National Hospital of Sri Lanka

Corresponding Author: Sepalika Mendis

E-mail: sepalikamendis@yahoo.com

Abstract

Coarctation of aorta (CoA) is a congenital abnormality which can have poor outcome without early intervention. Transcatheter intervention is the preferable modality of therapy for CoA over surgery. A retrospective analysis of patients' records was done from 2002-2017, in the Institute of cardiology, National Hospital of Sri Lanka. 50 patients were included with an age range of 8 -50 years (Mean age was 23.2 years). Male to female ratio was 1.17:1. . Successful outcome was defined by a drop in pressure gradient >50% or <20mmHg. Majority, 54 % (n=27) had asymptomatic hypertension. All had preserved EF>60% and 50% had LVH on echocardiography. Bicuspid aortic valves were seen in 22.2%. Mean narrowest diameter of CoA was 4.77mm. The pre-procedural mean PG was 62.93mmHg and post- procedural PG was 11.79mmHg, the reduction was statistically significant (P=0.00). Majority showed interventional success (93.2%). Procedural failure was seen in 6.3%. Majority, n=39(78%) were free of complications. 10 patients (20%) maintained on long term follow up (84.8 +/-56.9 months). Majority of them had preserved EF. Only 1 patient developed TIA. The study showed that the transcatheter intervention in CoA shows immediate significant successful results, indicating it as an effective and safe procedure.

Keywords: Coarctation of aorta (CoA), trans catheter intervention

Introduction

Coarctation of Aorta (CoA) is a common congenital cardiac defect resulting in a discrete narrowing along the lumen of aorta, which can show anatomical variations ⁽¹⁾. The narrowing in the aortic lumen restricts flow of blood distal to that of the constriction ⁽²⁾ and results in a process of maladaptation overtime. Having a heterogeneous presentation, it can cause increased mortality by virtue of its impact on the cardiovascular system. Studies have demonstrated that when not intervened in a timely manner nearly 75% of patients with CoA die before they reached 50 years ⁽³⁾.

Correction of CoA was initially approached surgically, but the last four decades have seen advances in percutaneous intervention to the point where successful results have been achieved through endo-vascular intervention, initially through balloon dilation only, and subsequently the utilization of stents to place across the narrowest region. In the Institute of Cardiology, National Hospital of Sri Lanka transcatheter intervention for CoA has being done for the last 15 years successfully. In this brief report we attempt to ascertain the patterns of presentation, clinical, echocardiographic features, modality of intervention and immediate outcomes of coarctation of aorta patients who presented for transcatheter intervention.

Material and Methods

A retrospective analysis of patients' records were done from 2002-2017, in a tertiary cardiac specialist centre in Sri Lanka. 50 patients were included in the analysis.

Results

Number of CoA patients were n=50. Their age ranged from 8 to 50 years, with a mean age of 23.2 years. Males comprised 54% (n=27) of the population. Majority, 54% (n=27) had asymptomatic hypertension. Amongst those symptomatic, shortness of breath was the commonest n=10 (43.4%). Headache was seen in n=4 (17.3%) of symptomatic patients. Most, n=25 (50%) had LVH on 2D echo. All had preserved EF >60% on initial workup. Eighteen (36%) had co existing structural abnormalities other than CoA. Valvular abnormalities were the commonest n=13 (72.2%). Bicuspid aortic valves were seen in n=4 (22.2%), aortic and mitral regurgitation were each seen in n=3 (16.6%). The narrowest diameter was 1.5mm, and the maximum observed diameter was 15.4mm. Mean was 4.77mm. Eighteen (36%) underwent only balloon dilation, while n=25 (50%) underwent direct stenting.



Overall procedural intervention was successful, as the pre-procedural mean PG was 62.93mmHg and post-procedural PG was 11.79mmHg, the reduction was statistically significant ($P=0.00$). Assessed separately the mean pressure gradient (PG) before intervention in the balloon dilation patients was 63.88 ± 33.87 mmHg, and 62.24 ± 21.55 mmHg in the direct stented patients. Post intervention PG was 20.33 ± 22.5 mmHg and 5.64 ± 9.7 mmHg in the balloon dilation and direct stenting group respectively. However there was no statistical significance between the mean pressure gradient difference (42.59 mmHg and 54.71 mmHg respectively) following intervention in between left or right arms ($P=0.775$). Majority showed interventional success $n=41$ (93.2%) [Defined as a drop in pressure $>50\%$ or <20 mmHg]. Procedural failure was seen in $n=3$ (6.3%) of the analyzed populace, of which $n=2$ belonged to the balloon dilation arm. Majority, $n=39$ (78%) were free of complications. Four patients had complications. Aneurysm formation & dissection were each noted in $n=1$ (2%) respectively. Only $n=10$ (20%) maintained long term follow up. Of those followed up, the mean duration of follow up was 84.8 months, with a standard deviation of 56.9 months. Most $n=9$ had preserved ejection fraction. Most $n=9$ showed insignificant residual pressure gradient across CoA. Five remain symptomatic, $n=3$ complaining of shortness of breath and $n=2$ complaining of chest pain. Most $n=6$, had good control of blood pressure. Only 1 patient developed a transient ischemic attack.

Conclusion

Transcatheter intervention of CoA appears to show immediate significant success, indicating that it as an effective procedure. Balloon dilation alone or direct stent insertion has good immediate outcome. Overall transcatheter management of CoA is a safe procedure. Complications though uncommon can be life-threatening. Long term residual persistence of symptoms and hypertension necessitate the need for better follow up.

References

1. Torok RD, Campbell MJ, Fleming GA, Hill KD. Coarctation of the aorta: Management from infancy to adulthood. *World Journal of Cardiology*, 2015; 7(11): 765-75.
2. Vergales JE, Gangemi JJ, Rhueban KS, Lim DS. Coarctation of the Aorta - The Current State of Surgical and Transcatheter Therapies. *Current Cardiology Reviews*, 2013; 9(3): 211-9.
3. Warnes CA, Williams RG, Bashore TM, Child JS, Connolly HM, Dearani JA, et al. ACC/AHA 2008 Guidelines for the Management of Adults with Congenital Heart Disease: a report of the American College of Cardiology/American Heart Association Task Force on Practice Guidelines (writing committee to develop guidelines on the management of adults with congenital heart disease). *Circulation*, 2008; 118(23): e714-833.



Author guidelines

Submitting a manuscript to the journal

From the Editorial Desk

Congratulations! You have reached the most important page of the journal. This section will provide all the necessary instructions to ensure your submission to the SLJC conforms to the standards and format applicable to the journal.

Submissions to the SLJC is via the email

△: srilankanjournalofcardiology@gmail.com

All submissions will be subjected to internal peer review and external review will be solicited at the discretion of the editorial board.

The manuscript should have a **Title page**, which should include *a) title, b) author names & institutional affiliations, c) corresponding author d) contact information of the corresponding author email and contact number* (The contact number will be available only to the Editor in chief and will not be published).

The manuscript should contain an **abstract**, limited to 250 words, with sections on *introduction, methods, results, discussion and conclusions and keywords* (format may vary according to the type of manuscript).

The body of the manuscript should include

a) introduction, b) results and findings or case report, c) discussion d) conclusion e) references. Where applicable please include a) acknowledgements b) conflicts of interest statement, c) consent d) ethical approval.

In regard to references, please utilize an accepted referencing software and avoid manual input. The style to be utilized is “numbered”. Use a ^(..) for the reference within the text with a relevant number. Example of reference is as follows.

Bitigen, A., et al., *Mitral regurgitation and ventricular septal defect as a complication of penetrating cardiac trauma: a case report*. Turkish Thoracic Cardiovascular Surgery Magazine, 2010. 18⁽¹⁾: p. 058-060.

Additionally, patients suffering from anxious and depressive disorders are more likely to have increased activity of sympathetic nervous system ⁽²³⁾ and subsequently catecholamine overload ^(23, 25).

The manuscript should be typed in

- Font :Times New Roman.Size12
- Headings Font : Calibri Size 14
- with double line spacing
- and should include page numbering
- use SI units: Please ensure that all special characters used are embedded in the text
- and should not have breaks in your manuscript

File formats which are accepted for submission include Microsoft word (DOC, DOCX).

In regard to preparing figures, please follow the formatting instructions below.

- Figures should be provided embedded in the main manuscript file in the correct position.
- Figures should **ALSO** be provided as separate files (not embedded in the main manuscript file).
- Each figure of a manuscript should be submitted with acceptable quality.
- Tables should submitted included in the main manuscript file.
- Multi-panel figures (those with parts a, b, c, d etc.) should be submitted as a single composite file that contains all parts of the figure.




- Figures should be numbered in the order they are first mentioned in the text, and uploaded in this order along with an appropriate title.
- Figure titles (max 20 words) and legends (max 200 words) should be provided in the main manuscript, and also in the graphic file.
- Each figure should be closely cropped to minimize the amount of white space surrounding the illustration.
- Individual figure files should be within 5 MB if *possible*. If a suitable format is chosen, this file size is adequate for extremely high quality figures.
- Please note that it is the responsibility of the author(s) to obtain permission and consent where and when relevant.

When creating and including tables please follow the formatting instructions below.

- Tables should be numbered and cited in the text in sequence using Arabic numerals (i.e. Table 1, Table 2 etc.).
- Tables less than one A4 or letter page in length can be placed in the appropriate location within the manuscript.
- Tables larger than one A4 or letter page in length can be placed at the end of the document text file. Please cite and indicate where the table should appear at the relevant location in the text file so that the table can be added in the correct place during production.
- Table titles (max 20 words) should be included above the table, and legends (max 200 words) should be included underneath the table.
- Tables should not be embedded as figures or spreadsheet files, but should be formatted using 'Table object' function in your word processing program.
- Color and shading may not be used.

We hope these instructions are simple and easy to follow and look forward to your submission for our next issue.



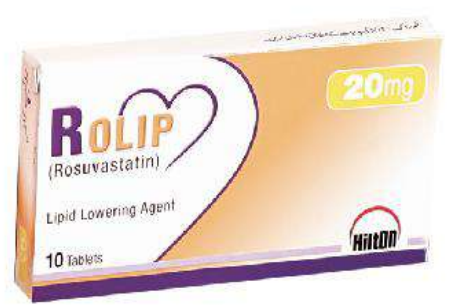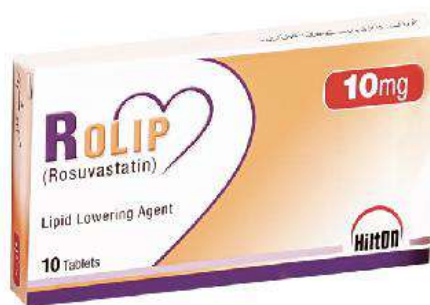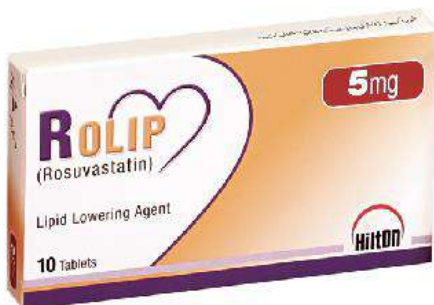**Sri Lanka
College of
Cardiology**

ROLIP
Rosuvastatin 5, 10 & 20 mg Tablet

FROM
ACTION to
PREVENTION



- Robust risk reduction in CVD
- Effectively rises HDL-C
- First Line treatment in primary prevention
- Recommended by 2019 ACC / AHA Guideline



Working Towards a Healthy Future...

Hilton Pharma (Pvt.) Ltd.

Progressive Plaza, Beaumont Road, Karachi - Pakistan.
UAN: (021) 111-123-000 Web: www.hiltonpharma.com