Case Report

Percutaneous Closure of Left Main Coronary Artery to Right Atrial Fistula: A Case report with important transcatheter techniques.

Thushara Rodrigo[1], Duminda Samarasinghe[1]
1 Lady ridgeway Hospital for Children
Corresponding author: Thushara Rodrigo Email: ptmrodrigo@gmail.com

Abstract

Coronary artery fistulae are rare with a prevalence of 0.1- 0.2% in routine angiograms[1]. Most of the patients are picked up incidentally due to a continuous murmur. Fistulae can lead to angina, palpitations, syncope or even infective endocarditis.
Although surgery is the mainstay of treatment, close clinical follow up in asymptomatic patients and trans catheter device closure later are being practiced with successful outcomes.
We describe a 4-year-old boy, who was incidentally diagnosed with left main coronary artery to right atrial fistula during neonatal examination, successfully treated using Amplatzer® duct occluder 11 emphasizing new therapeutic approach to this rare clinical entity in a resource limited setting.
Key words – Coronary artery fistula, transcatheter closure, device closure

Case Report

Master K was referred for cardiac evaluation following neonatal examination at 4 days of life. Echocardiography revealed a small ostium secondum atrial septal defect with a small coronary to right atrial fistula. Since the baby was stable, he was reviewed regularly at the paediatric cardiology clinic at Lady Ridgeway Hospital for Children.

Master K was a well thrived child without complaints. He had good exercise tolerance and was attending to daily activities normally.

However, his echocardiographic evaluation revealed a gradually increasing fistulae without chamber dilatation, pulmonary hypertension or cardiac motion abnormalities. His clinical evaluation was normal apart from a continuous murmur best heard at left sternal border.

Although the child was asymptomatic he was taken up for cardiac catheterization to decide on future management. His echocardiogram prior to cardiac catheterization revealed left main coronary artery (LMCA) to right atria (RA) fistula, which ran posterior to aortic root, with two to three openings noted in RA. Cardiac catheterization confirmed the diagnosis and established suitability for catheter intervention (Figure 1).

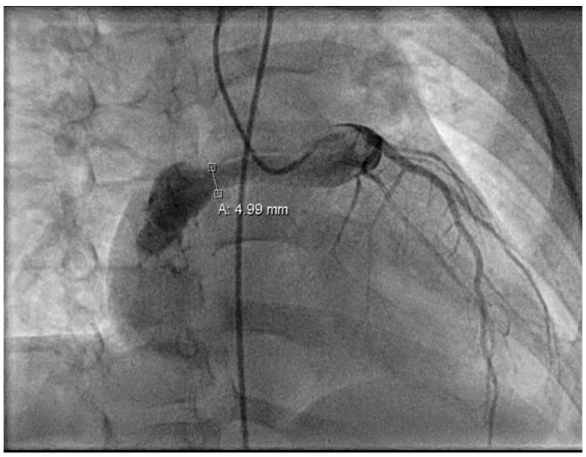

Figure 1

Master K was taken into the catheterization laboratory for the device closure of LMCA to RA fistula. Vascular access was obtained from right femoral vein and artery using 5F short sheaths. 4F pigtail catheter was advanced from right femoral artery to ascending aorta to perform an arch angiogram, which demonstrated coronary fistulae with its branching pattern and opening (Figure 1). Fistulae were engaged using 4F Left Coronary Artery Catheter (LCA) and 0.018 Terumo guidewire was advanced through the catheter (Figure 2) through fistulae to RA and then to Pulmonary Artery (PA). Venous end forming an arteriovenous loop across the fistulous tract (Figure 3).

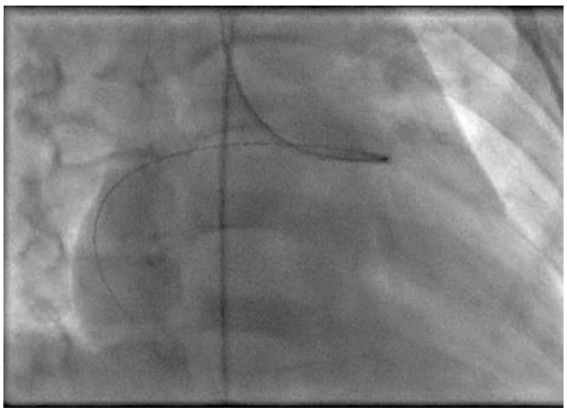

Figure 2

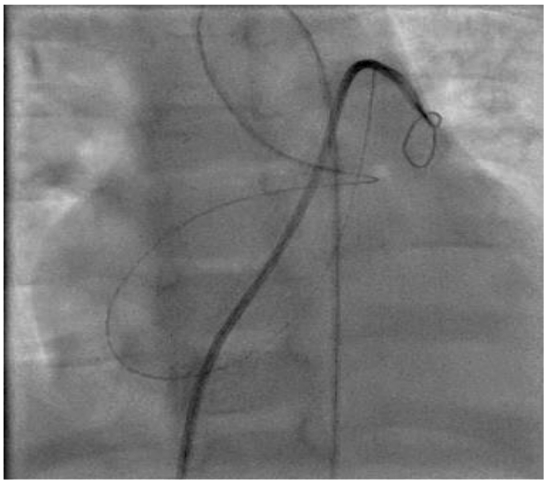

Figure 3

Then 4F pigtail catheter was passed through the 5F Amplatzer Duct Occluder (ADO) delivery system and using it as a dilator, the sheath was advanced into the mid part of the fistula. 6mm ×4mm ADO 11 device was advanced from the venous side through the delivery system and deployed in the middle part of the fistulous tract.

Check injections were done using the 4F LCA catheter in the arterial side. There were no ECG changes after positioning of the device. Device was successfully released after confirming the stability and position on angiograms. Post procedure angiogram revealed good device configuration without residual leaks or evidence of dissection (Figure 4). Child was hemodynamically stable and there were no ECG changes throughout the procedure.

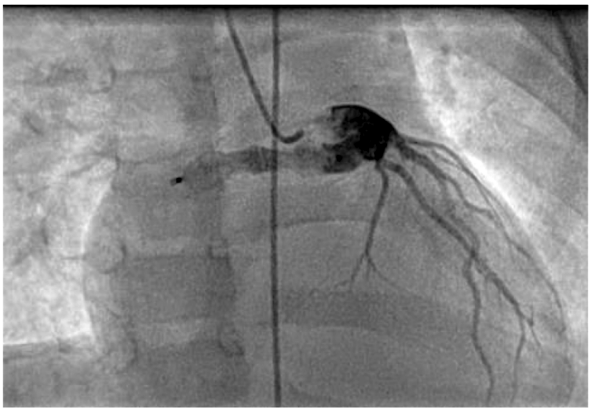

Figure 4

Post procedure echocardiogram showed no residual leak on following day. Master K was discharged on aspirin and clopidogrel. He will be reviewed at cardiology clinic in 4 weeks' time.

Discussion

Coronary artery fistulae (CAF) are rare congenital abnormalities connecting a coronary artery to a cardiac chamber or pulmonary artery. It represents 0.2-0.4% of congenital cardiac lesions where 50% are seen in relation to the right coronary, 35% in relation to left coronary and 5% with both coronaries [2]. CAF can be categorized into solitary and multiple micro fistulae. Acquired coronary arteriovenous fistula are seen following cardiac surgery, Kawasaki disease, Takayasu arteritis, pacing lead erosion and chest trauma [3].

Lack of symptoms is the main diagnostic challenge in coronary artery fistulae. Only 10-20% of patients with coronary arteriovenous fistula presents with symptoms [1].

Described clinical sequelae are coronary artery dissection/ intramural rupture leading to cardiac tamponade, myocardial ischemia and adjacent structure compression due to aneurysms[1]. Also it can lead to increased pulmonary blood flow which can lead to heart failure and hyperkinetic pulmonary hypertension [4]. Another important complication described in the literature is infective endocarditis.

Significant clinical presentations are mainly due to diastolic aortic runoff, pulmonary over circulation and distal coronary insufficiency.

Coronary angiography is the gold standard investigation to delineate the anatomy and shunt calculation. Newer imaging modalities like multidetector computed tomography and MRI can also clearly demonstrate coronary anatomy including the origin, drainage and course [5]. Noninvasive investigations are helpful when there are contraindications for cardiac catheterization under general anaesthesia and cardiac catheterization does not provide sufficient anatomical data.

Our patient was completely asymptomatic with good exercise tolerance. However, it is well documented that complications secondary to this particular clinical entity increase with age. Some authors argue of the value of intervention without documented physiologic burden from the fistulae while others intervene prior to the development of complications[6]. However, we decided to intervene in our patient after 4 years of follow up which demonstrated progressive enlargement of fistulae probably leading to complications in later life. According to the classification published by Said et al CAF is defined as small if the vessel diameter is less than 2mm, medium if the diameter is 2-8mm and large if the diameter is 8mm [7]or more.

Best management of CAF needs thorough evaluation of patient's clinical presentation, anatomy of the fistulae, flow dynamics and associated cardiac disorders[8]. Therapeutic interventions are mainly surgical[9] and transcatheter closure of the fistulae. Each modality of intervention has its limitations and benefits.

Complications encountered during surgery are myocardial infarction, arrhythmia, transient ischemic changes and stroke [9]. On the other hand, transcatheter intervention has lesser morbidity and mortality, lower cost, short recovery time and avoidance of thoracotomy and cardiopulmonary bypass [10]. Transcatheter intervention also has complications such as arrhythmias, contrast related complications, coil embolization and fistula dissection [11].

First percutaneous intervention for a CAF was done by Dr Reidy et al [12]. Since then various devices have been used for percutaneous intervention including coils, device, duct occluders, vascular plugs and chemicals including cyanoacrylate.

Important facts and complications of various percutaneous intervention modalities are summarized in following table [13].

Method	Important facts	Complications
Coil embolization	Commonly preferred method. Unfavorable conditions for coil embolization – distally located fistulae, adjacent vessel at risk, larger fistulae Can use multiple coils. Mainly 2 types – standard steel coils and platinum micro coils.	Transient arrhythmias, coil embolization into larger vessel, recoil into major coronary artery leading to myocardial infarction.
Detachable balloons	No longer preferred. Reliable and safe method to occlude large CAF.	Available data are limited.
AMPLATZER® vascular plug	Self-expandable, cylindrical device made of Nitinol mesh wires. High rate of occlusion without the need for delivery of multiple occlusion devices.	

AMPLATZER® duct Occluder	Self-expandable, made of Nitinol wire mesh. Use to close PDA. Advantages – high rate of complete occlusion, ante grade placement, ease of placement and improved control during deployment.	
Covered stents	Mainly preferred in accompanying atherosclerotic lesions and in plexus like fistulae.	Side branch occlusion, stent restenosis and stent thrombosis.
Chemicals	Used chemicals - Gel foam and polyvinyl alcohol foam or liquid materials such as N-butyl cyanoacrylate. Can combine with coil embolization to occlude residual connections.	

Decision regarding device occlusion was taken after the proper analysis of the fistula anatomy following the angiogram. Proximal origin of fistula, absence of multiple feeders and drainage to low pressure areas were the main factors considered in deciding percutaneous intervention [10]. Occlusion device selection mainly depends on associated cardiac lesion, age of the patient and anatomy of the fistulae.

We used AMPLATZER® Duct Occluder 11 (ADO 11) in our patient mainly due to its high success rate, improved control over release and use of low profile catheters [14]. Also practical reasons like availability, cost effectiveness and high experience with the device were considered.

Sizing of the device is also important as large devices results insufficient wrapping and smaller devices have the risk of embolization. We used 6mm×4mm ADO 11 device considering the 30% larger sizing compared to the size of the fistulae [14].

We made an arteriovenous loop through the fistulous tract after snaring the guidewire in the pulmonary artery. Initial attempts to snare the guidewire at right sided cardiac chambers were unsuccessful probably due to larger space. Therefore, we used the fairly narrow space at pulmonary artery to snare the guidewire which is an important strategy.

Proper analysis and decision regarding the site of device delivery is very important so that it will prevent device migration and clot propagation. In our case we delivered the device after verifying the fistula anatomy and continuously monitored ECG for ischemic changes. It is always advisable to observe for ECG changes during the device deployment and soon after the delivery of the device.

Device deployment in both antegrade and retrograde fashion are acceptable according to the available literature. In our scenario we decided to deploy the device after entering through the right atrial end of the fistula purely because of the difficult angle we might need to take if we approached through the arterial side. Other advantage is the ability to use larger and straighter catheter during the antegrade approach. On the other hand, this method carries the risk of embolization due to lack of flow control.

In the literature there are reports of successful closure of CAF located near to the adjacent vessel and CAF with multiple drainage sites [10]. According to our experience we suggest surgical intervention in those scenarios in resource limited settings.

Gentle manipulation of catheters during the intervention is very important to prevent complications such as vessel rupture and dissection [10]. Our child did not have any acute complications mainly due to smooth catheter manipulation and close monitoring.

Close follow up is warranted as there is persistent coronary artery dilatation after intervention[15] and rupture of CAF irrespective of coronary dilatation. Although there are no uniform consensus regarding anticoagulation following intervention, some authors found it helpful to start antithrombotic agents for dilated coronaries as there is high chance of stagnation and thrombus formation [15]. Other long term complications would be recanalization, late thrombosis and myocardial ischemia. Therefore, long term follow-up has been arranged for our patient.

Conclusion

Percutaneous intervention of CAF is a safe and successful method. We discuss a patient who underwent successful device closure of CAF using important interventional techniques comparing the methods employed in literature. It is evident that correct selection of patients and delineating the fistula anatomy is the cornerstone of successful management of CAF. Also selecting the correct device will reduce the rate of complications and considering the physiological background to practical clinical scenario leads to effectiveness. We also highlight the importance of meticulous long term follow up which will produce important data for future studies.

Reference

1. *Liberthson RR, Sagar K, Berkoben JP, et al. Congenital coronary arteriovenous fistula. Report of 13 patients, review of the literature and delineation of management. Circulation 1979;59:849–54.*
2. *Levin DC, Fellows KE, Abrams HL. Hemodynamically significant primary anomalies of the coronary arteries. Angiographic aspects. Circulation 1978, 58:25.*
3. *L. Luo, S. Kebede, S. Wu, G.A. Stouffer Coronary artery fistulae Am J Med Sci, 332 (2006), pp. 79-84.*
4. *Shiga Y, Tsuchiya Y, Yahiro E, et al. Left main coronary trunk connecting into right atrium with an aneurysmal coronary artery fistula. Int J Cardiol 2008;123:e28–30.*
5. *Weymann A, Lembcke A, Konertz WF: Right coronary artery to superior vena cava fistula: imaging with cardiac catheterization, 320-detector row computed tomography, magnetic resonance imaging, and trans esophageal echocardiography. Eur. Heart J. 30(17), 2146 (2009).*
6. *Macri R, Capulzini A, Fazzini L, Cornali M, Verunelli F, Reginato E: Congenital coronary artery fistula: report of five patients, diagnostic problems and principles of management. Thorac. Cardiovasc. Surg. 30(3), 167–171 (1982).*
7. *Said SA, Van Der Werf T: Dutch survey ofvcoronary artery fistulas in adults: congenitalvsolitary fistulas. Int. J. Cardiol. 106(3), 323–332 (2006).*
8. *Kamiya H, Yasuda T, Nagamine H et al.: Surgical treatment of congenital coronary artery fistulas: 27 years' experience and a review of the literature. J. Card. Surg. 17(2), 173–177 (2002).*
9. *Gajjar T, Voleti C, Matta R, Iyer R, Dash PK, Desai N. Aorta-right atrial tunnel: clinical presentation, diagnostic criteria, and surgical options. J Thorac Cardiovasc Surg 2005;130:1287-92.*
10. *Armsby LR, Keane JF, Sherwood MC, Forbess JM, Perry SB, Lock JE. Management of coronary artery fistulae. Patient selection and results of transcatheter closure. J Am Coll Cardiol 2002;39:1026-32.*
11. *Behera SK, Danon S, Levi DS, Moore JW. Transcatheter closure of coronary artery fistulae using the Amplatzer Duct Occluder. Catheter Cardiovasc Interv 2006;68:242-8.*
12. *Reidy JF, Sowton E, Ross DN: Transcatheter occlusion of coronary to bronchial anastomosis by detachable balloon combined with coronary angioplasty at same procedure. Br. Heart J. 49(3), 284–287 (1983).*
13. *Mehemet Ali Oto, Hikmet Yorgun, Kudret Aytemir: Percutaneous approaches to closure of coronary artery fistulas. Interv. Cardiol (2011)3(1), 79-89.*
14. *Behera SK, Danon S, Levi DS, Moore JW. Transcatheter closure of coronary artery fistulae using the Amplatzer Duct Occluder. Catheter Cardiovasc Interv 2006;68:242-8.*
15. *Mcmahon CJ, Nihill MR, Kovalchin JP, Mullins CE, Grifka RG: Coronary artery fistula. Management and intermediate-term outcome after transcatheter coil occlusion. Tex. Heart Inst. J. 28(1), 21–25 (2001).*