Case Report

Recurrent hemoptysis following coronary artery bypass graft surgery: an uncommon presentation of pseudo aneurysm formation of the ascending aorta complicating surgery and a novel approach to its management, a case report.

Sepalika Mendis[1], Charitha Herath[1], Nadeeja Senevirathne1, Mitrakrishnan Navinan1, Prakash Priyadharshan[1]
1. Institute of Cardiology, National Hospital of Sri Lanka
Corresponding author S. Mendis Email: sepalikamendis@yahoo.com

Abstract

Background -Coronary artery bypass graft surgery is known to cause complications, of which pseudo-aneurysm formation of the ascending aorta is an uncommon presentation. Haemoptysis as a presenting feature of pseudo-aneurysm is also infrequent
Case presentation -A 66 year old South Asian male who underwent coronary artery bypass graft surgery in 2012 presented with recurrent hemoptysis since 2014. Excluding other etiological causes, the diagnosis of an active leaking pseudo-aneurysm of ascending aorta causing a haematoma eroding into pulmonary system was considered the culprit lesion.
Method- Using a Judkins right catheter®, a Terumo® wire was coiled into the aneurysmal sac, over which a Cook side arm Mullin sheath® was introduced and a Memo Part® atrial septal occluder device was introduced to successfully close the pseudo-aneurysm arising from the ascending aorta. Long term success was also confirmed with a contrast enhanced computer tomography scan 12 months later, which demonstrated no residual leak , an insitu occluder device and a symptom free patient.
Conclusion -Minimally invasive cardiac intervention has been gaining popularity with advancing technology and is becoming a preferential modality of treatment by both the patient and interventionist alike. Adapting to available technology and using novel approaches can yield excellent results when anatomy and clinical situations are suitable. Atrial septal occlude devices can be used to close pseudo-aneurysms of the aorta, when anatomically favourable.
Keywords: Device closure, pseudo-aneurysm, hemoptysis, CABG, ASD occluder device

Background

Coronary artery bypass surgery (CABG) is a life-saving surgical procedure, but is not without its fair share of risks. Vascular complications such as pseudo-aneurysm (PA) formation is a rare phenomenon following CABG. It can be attributable to many causes during the traumatic surgical procedure e.g. vessel clamping, cannulation, sutures, sites of vessel grafting and infection [(1)]. The way in which the pseudo-aneurysm manifests itself can also be highly variable. Haemoptysis as a primary presentation is an uncommon, but documented phenomenon in medical literature [(2)]. Though surgical correction is an option, the complexities of altered anatomy and challenges faced with repeat cardiothoracic surgery including that of potentially increased risk of on table and post-operative mortality and morbidity adds to the burden of decision the surgeon has to make. The evolution of minimally invasive cardiac interventions has led to the advent of utilization of currently available devices and instruments in novel ways, which diverge from their recommended and approved use. These include stent grafts, coils, thrombin injection and even occluder devices [(3)].

In this case report, we describe a patient who developed PA as a complication following CABG and presented with recurrent and worsening hemoptysis, in whom we utilized a novel approach in a resource limited setting and successfully closed a pseudo-aneurysm using a Memo Part® atrial septal occluder device.

Case presentation

A 66 year old South-Asian male, who was known to have hypertension and dyslipidemia underwent coronary artery bypass grafting for severe triple vessel disease in 2012. He made a successful recovery following surgery, but was plagued with fever three months later for which he underwent extensive investigation due to his background surgical history and was incidentally found to have an aortic pseudo-aneurysm in the ascending aorta (Fig 1). Due to its asymptomatic nature, incidental finding and clinical complexity involved if redo surgery was to be undertaken (due to altered anatomy), a clinical decision was taken to initially manage it conservatively with periodic observation. The preliminary decision was proven correct as the patient remained well. But In 2014, 2 years after the initial discovery the patient began to develop infrequent episodes of hemoptysis, which worsened gradually with time, specifically three months prior to his presentation in 2016.

Case Report

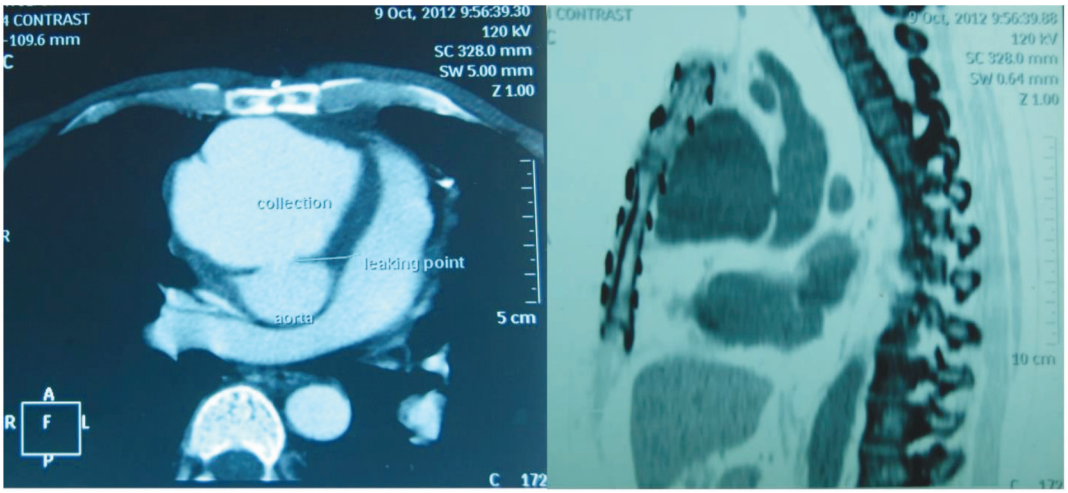

Figure 1 Fig 1: **Preliminary diagnosis of pseudo-aneurysm:** Contrast enhanced CT chest and aorta done in 2012 shows both on the transverse view(left image) and the sagittal view(right image) a well defined large (4.8cmX6.3cmX5.8cm) collection , located retro-sternally and anterior to the ascending aorta suggestive of haematoma , arising from the ascending aorta, with an opening diameter of 8.8mm.

Despite this, he remained free of angina with good exercise tolerance. On clinical examination, the gentleman though mildly pale, had no other significant findings on general examination. His cardiovascular examination demonstrated only elevated blood pressure with a systolic value of 160 mmHg and a diastole value of 90mmHg. The respiratory examination failed to reveal any significant findings and remainder of the systemic examination was normal.

An extensive investigational assessment was done to rule out common causes of hemoptysis. His whole blood analysis revealed mild anemia with a hemoglobin of 10.8 g/dL (12-15) with a preserved mean corpuscular cell volume and concentration. His platelet counts were within reference range. Coagulation studies failed to reveal any abnormalities. Electrocardiographic study was normal. Imaging of the chest with chest X-ray revealed a wide mediastinum and a follow through with a contrast enhanced computed tomography of the chest along with an aortography revealed an out- pouching of 4.3 cm X 5.5 cm with a neck of 7mm attached to ascending aorta 3.2cm from the root, and demonstrated active leak outside with a large haematoma formation, in direct contact with the sternum (Fig 2) A trans-esophageal echo was also done and this demonstrated and confirmed the lesion.

A working diagnosis of aortic pseudo-aneurysm eroding into the bronchus was made and was deemed responsible for this patient's presentation of recurrent hemoptysis.

Due to the risk associated with redo surgery and severity of symptoms necessitating early treatment, a collaborative multidisciplinary decision was taken to approach this case with a minimally invasive transcatheter approach and to attempt closure with an occluder device, and to go for immediate surgery if this failed.

Procedure

The entire procedure was done under local anesthesia. To gain vascular entry right femoral arterial access was secured with a 7Fr sheath. Adequate anticoagulation was given with intravenous heparin in accordance to bodyweight.

A marker pigtail catheter was placed for guidance in the aortic root. In addition to CT-aortogram, an on table aortogram was also done and the neck of the pseudo-aneurysm was re-measured, and was found to be 9.2mm. Using a Terumo 0.032 inch, 260 cm wire a Judkins Right catheter was used to gain access into the narrow neck of the pseudo-aneurysm. The Terumo wire was coiled within the aneurysmal sac. To secure access to deliver the atrial septal occluder device, we initially attempted to use a 9 Fr Amplatzer delivery sheath, however this was unsuccessful due to the angle of entry and rigidity of the sheath. Finally a 9Fr Cook side arm Mullin sheath was used and yielded success. A 16mm waist size Memo part® atrial septal occulder device was used to close the pseudo-aneurysm. Final aortogram showed excellent results with complete occlusion of the pseudo-aneurysm and accurate device positioning (Fig 3A-3I).

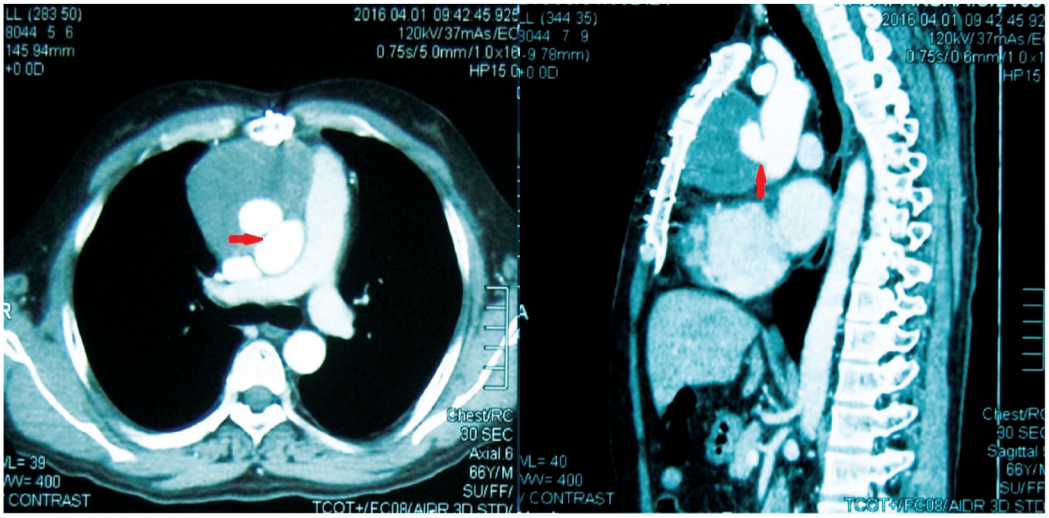

Figure 2 : **Enlarging hematoma from the pseudo-aneurysm**: Contrast enhanced CT chest and aorta done in 2016 shows both on the transverse view(left image) and the sagittal view(right image) a well defined large (7.6cmX5.5cm) haematoma (indicated by black arrow) , surrounding a 18mmX15mm pseudo aneurysm with a neck of 12mm with ongoing active leak (indicated by red triangle), arising from the ascending aorta located retro-sternally and anterior to the ascending aorta, suggesting enlargement from what was seen in 2012.

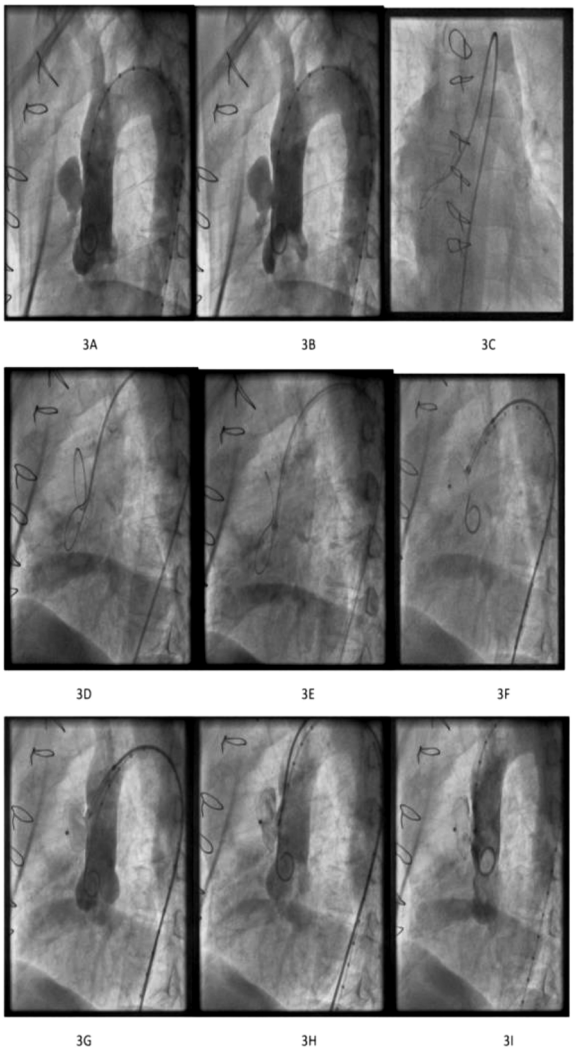

Figure 3A – 3I -One year post procedure: Contrast enhanced CT chest and aorta done in 2017, 12 months post closure shows on the sagittal view persistence of the pseudo aneurysm with no active leak, and the surrounding haematoma has reduced in size measuring only 2.6cm x 5.5cm (indicated by black arrow) and the atrial septal occluder device is present without any complications being observed(indicated by red triangle) .

Follow-up.

1 year after the surgery, the patient remains free of symptoms and a repeat contrast enhanced CT-aortogram done revealed a reduction in the size of the hematoma with no active leakage with the occluder device being in the correct position and placement with no complications due to the Memo part® ASD occluder device as well(Fig 4). 4 years later the patient still remains symptom free and is seen in regular clinic follow-up.

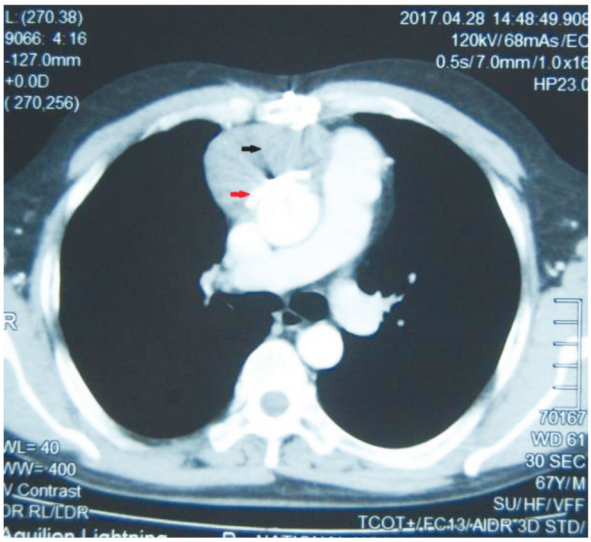

Figure 4

Discussion

Percutaneous intervention has been gaining popularity over traditional surgical option in consideration of numerous cardiac conditions in recent years, due to the rapidly evolving nature of available technology. With comparatively lesser morbidity and mortality and with patient preference leaning towards a minimally invasive non-surgical approach, has led interventionists to venture and succeed in utilizing available technology in novel ways. The off label use of ASD device occluders to close aortic pseudo-aneurysms is a prime example. Though still uncommon and few in number, the available literature favors device closure of PA when anatomy of the PA and surrounding structures are appropriate and favorable with an appropriately oversized occlude [4]. Our patient had recurrent hemoptysis, and active leak was observed, suggesting the fragile nature of the haematoma. This posed a restriction of using less stiff wires to secure access to prevent potentially catastrophic bleeding events, hence our reasoning for choosing Terumo wire.

Furthermore to achieve procedural success, we coiled the soft Terumo wire within the aneurysmal sac, to gain necessary stability to advance the delivery sheath. From our experience and available literature we can assume, though the overall principle remains the same, no single delivery system should be considered standard, as different forms of wires, techniques and delivery sheaths have been utilized in individual cases and case series with variable success and failure [4-6], implying the need to improvise to overcome and adapt to the variable anatomical origins, presentations and possible restrictions PA can pose, as in our case. A suitable device should also be chosen based on anatomy, waist size, symmetry. Considering the thin wall of the vessels as well as the PA and anatomy of PA, a relatively narrow waist device such as atrial septal occluder was considered optimal for this patient. Follow up is also important to ensure to identify potential complications occluder devices may cause specially erosion, device embolization and a nidus for infection emphasizing the need for both short term and long term assessment with sufficient imaging to ensure procedural success and vigilance. In this case report we wish to emphasize the unique presentation of both the pseudo-aneurysm and the improvised alternate method of access and delivery system utilized to successfully close it resulting in good long term outcome.

Conclusion

Common symptoms such as haemoptysis can have atypical causes, and when occurring following a history of CABG, clinicians must recognize and appreciate rare complications such a pseudo-aneurysm of the ascending aorta with haematoma formation with erosion as potential aetiology into differential diagnosis. Percutaneous intervention with device closure can offer a minimalistic yet complete solution, with lesser risk to comparative to open surgery even in complex presentations, such as pseudo-aneurysm formation of the ascending aorta. Interventionists should not be dissuaded and should adapt with available hardware and use alternate modalities of delivery suitable to the anatomy of the presenting situation to achieve procedural success. ASD occluder devices can be used in appropriate situations to device close pseudo-aneurysm of aorta.

List of abbreviations

CABG-Coronary artery bypass graft

PA-Pseudoaneurysm

ASD-Atrial septal defect

Declarations

Consent for publication

Consent was taken from the patient to publish this case vignette including permission for the images and videos.

Availability of data and materials

All relevant data are included within this case report as images and videos.

Competing interests

None

Funding

None

Authors' contributions

SM, CH diagnosed the case. SM, RN, PP researched and drafted the manuscript. All authors provided care for the patient. All authors were involved in the procedural therapy for the patient.

Acknowledgements

We would like to acknowledge the Cardiac Catheter lab staff of Institute of Cardiology, National Hospital of Sri Lanka.

References

1. *Sullivan KL, Steiner RM, Smullens SN, Griska L,Meister SG. Pseudoaneurysm of the ascending aorta following cardiac surgery. Chest. 1988;93(1):138-43.*
2. *Nair G, Jindal S, Chandra A, Swami S, Garg P. Haemoptysis - a rare presentation of aortic ane urysm. Lung India : official organ of Indian Chest Society. 2008;25(1):20-1. doi:10.4103/0970-2113.44133.*
3. *Stasek J, Polansky P, Bis J, Brtko M, Klzo L, Babu A et al. The percutaneous closure of a large pseudoaneurysm of the ascending aorta with an atrial septal defect Amplatzer occluder: two-year follow-up. The Canadian journal of cardiology. 2008;24(12):e99-e101.*
4. *Agarwal M, Ray M, Pallavi M, Sen S, Ganguly D, Joshi P et al. Device occlusion of pseudoaneurysm of ascending aorta. Annals of pediatric cardiology. 2011;4(2):195-9. doi:10.4103/0974-2069.84675.*
5. *Scantlebury DC, Alli OO, Joyce LD, Rihal CS. Percutaneous device closure of a pseudoaneurysm arising from the junction of the innominate artery and the aorta. The Journal of thoracic and cardiovascular surgery.2012;144(3):732-4. doi:10.1016/j.jtcvs.2012.03.069.*
6. *Hussain J, Strumpf R, Wheatley G, Diethrich E. Percutaneous closure of aortic pseudoaneurysm by Amplatzer occluder device-case series of six patients. Catheterization and cardiovascular interventions : official journal of the Society for Cardiac Angiography & Interventions. 2009;73(4):521-9. doi:10.1002/ccd.21833.*